

Aphasia With Predominantly Subcortical Lesion Sites

Description of Three Capsular/Putaminal Aphasia Syndromes

Margaret A. Naeser, PhD; Michael P. Alexander, MD; Nancy Helm-Estabrooks, DSc;
Harvey L. Levine, MD; Susan A. Laughlin, MA; Norman Geschwind, MD

• Nine cases of subcortical aphasia with capsular/putaminal (C/P) lesion sites demonstrated on computed tomographic (CT) scans were studied. Eight cases were occlusive-vascular in etiology and one was hemorrhagic. Three subcortical aphasia syndromes and three C/P lesion site patterns were observed. Patients with C/P lesion sites with anterior-superior white-matter lesion extension had good comprehension, grammatical, but slow, dysarthric speech, and lasting right hemiplegia. Patients with C/P lesion sites with posterior white-matter lesion extension across the auditory radiations in the temporal isthmus had poor comprehension, fluent Wernicke-type speech,

and lasting right hemiplegia. Patients with C/P lesion sites with both anterior-superior and posterior extension were globally aphasic and had lasting right hemiplegia. Although these cases of C/P subcortical aphasia shared certain well-known features of Broca's and Wernicke's cortical aphasia syndromes, they did not completely resemble cases of either Broca's, Wernicke's, global, or thalamic aphasia in neurologic findings, CT scan lesion sites, or language behavior. Further study of the subcortical aphasias associated with these C/P lesion sites seems to be warranted.

(Arch Neurol 1982;39:2-14)

The well-known syndromes of language dysfunction, eg, Broca's or Wernicke's aphasia, have clearly established relationships to lesions in specific cortical sites. The purpose of this article is to present clinicoanatomic correlations observed in nine cases of aphasia with predominantly subcortical lesion sites that involved

primarily the internal capsule and the putamen. The term *subcortical aphasia* is used in this article to refer to aphasia that results from lesion sites that are largest *medially*,—ie, in the internal capsule, putamen, or periventricular white matter (PVWM). These subcortical lesions only extend laterally toward the cortex, and may include small patches or parts of the cortex. In no instance is large lesion present in the pars triangularis, pars opercularis (Broca's area) or the posterior half of the superior temporal gyrus (Wernicke's area), or the supramarginal or angular gyri. The term *cortical aphasia* is used in the article to refer to aphasia that results from lesion sites that are largest in size *laterally*, ie, in the frontal, temporal, or parietal cortical areas. These cortical lesions only extend medially, toward the deep structures, but do not necessarily include these structures. The direction of the lesion distribution is completely different in the subcortical vs the

cortical aphasia syndromes. The important difference in vascular involvement will be discussed further.

See also p 15.

In the patients in our study, three predominantly subcortical lesion site patterns were observed: (1) capsular/putaminal (C/P) with anterior-superior white-matter lesion extension, (2) C/P with posterior white-matter lesion extension, and (3) C/P with both anterior-superior and posterior lesion extension. Each anatomic pattern was associated with a specific aphasia pattern. These subcortical aphasia syndromes seemed to be distinctive because they resembled neither the well-known cortical aphasia syndromes nor the previously reported subcortical speech-language disorders.¹⁻¹²

METHODS

Patients were initially examined at outside hospitals and later at either the Boston or Palo Alto (Calif) Veterans Administration medical centers. Major clinical neurologic information for each case is given in Table 1. Language was formally evaluated with the Boston Diagnostic Aphasia Examination (BDAE),¹³ and test results are given in Table 2. Lesion sites were assessed with computed tomographic (CT) scans. Behavioral testing was carried out before the CT scans were done or reported.

Computed tomographic scan slice labels, B, B/W, W, SM, and SM + 1, were used as defined in previous CT scan aphasia studies¹⁴⁻¹⁷: slice B contained Broca's area lateral to the left frontal horn; slice B/W, Broca's area lateral to the left frontal horn and Wernicke's area lateral to the third ventricle (the internal capsule and putamen are viewed best at slice B/W); slice W, Wernicke's area anterior and lateral to the

Accepted for publication April 20, 1981.

From the Department of Neurology, Boston University School of Medicine, and the Aphasia Research Center, Boston Veterans Administration Medical Center (Drs Naeser, Alexander, and Helm-Estabrooks); the Department of Radiology, Tufts University Medical School and Boston VA Medical Center (Dr Levine); the Audiology and Speech Pathology Service, Palo Alto (Calif) VA Medical Center (Ms Laughlin); and the Neurological Unit, Beth Israel Hospital, Boston (Dr Geschwind). Dr Geschwind is the James Jackson Putnam Professor of Neurology at Harvard Medical School, Boston.

Read in part at the Academy of Aphasia meeting, San Diego, Oct 16, 1979.

Reprint requests to VA Medical Center (116-B), 150 S Huntington Ave, Boston, MA 02130 (Dr Naeser).

Table 1.—Major Clinical Neurologic Findings

Case/Age at Onset, yr/Sex	Etiology	Time of Examination	Deficit*			Sensorium at Onset
			Motor	Sensory	Visual Field	
1/53/M	Occlusive-vascular	3 mo after stroke	C/P With Anterior-Superior Lesion Extension†			Alert from onset
			R hemiparesis, arm > leg, some R hand movement	...	None	
2/64/F	Occlusive-vascular	1 wk	R hemiplegia, arm > leg	Unremarkable to gross testing	R visual field cut	Alert from onset
3/45/M	Occlusive-vascular	1 mo after stroke	Dense R hemiparesis, arm > leg	...	None	Relatively alert from onset
4/43/M	Hemorrhage	3 mo after stroke	C/P With Posterior Lesion Extension			Comatose within hours, lethargic until 1 mo after stroke
			R hemiparesis, arm > leg, some fine finger movement at 4 mo after stroke	Mild	R visual field deficit	
5/62/M	Occlusive-vascular	1 mo after stroke	Severe R hemiplegia	Mild	R homonymous hemianopsia	Initially unconscious, then stupor for first hr, later alert
6/64/M	Occlusive-vascular	10 days	R hemiplegia	Mild, RUE	R visual field deficit	Alert from onset
7/64/M	Occlusive-vascular	Onset	C/P With Both Anterior-Superior and Posterior Lesion Extension			Alert from onset, agitated
			R hemiplegia	Mild	Dense R hemianopsia	
8/59/M	Occlusive-vascular	3 mo after stroke	R hemiplegia, arm > leg	...	R visual extinction	Somnolent, soon alert, emotionally labile
9/68/M	Occlusive-vascular	Onset	R hemiplegia, arm > leg	Mild	R homonymous hemianopsia	Alert from onset

*R indicates right; RUE, right upper extremity.

†C/P indicates capsular/putaminal.

left atrium; and slices SM and SM + 1, the supramarginal gyrus, lateral to the posterior half of the body of the left lateral ventricle. The lesion sizes were computed in two ways: (1) number of 1-sq mm pixels present in the lesion and (2) percent of tissue damage in the left hemisphere.¹⁸ Lesion size was particularly important in the higher slices, ie, SM or SM + 1.

The term "C/P with anterior-superior extension" is used in this article to describe C/P lesion areas that extended anteriorly in PVWM, deep to Broca's area at slices B and/or B/W, and superiorly in PVWM-corona radiata at slices SM and SM + 1. Ross¹⁹ has shown that at the level of the body of the lateral ventricle (slices SM and SM + 1), the pyramidal tract courses through the white matter just lateral to the middle portion of the body of the lateral ventricle. The cortical representation of the face, lips, and tongue on the motor homunculus is parallel to the body of the lateral ventricle. Hence, the face, lips, and tongue area, as well as white matter of the pyramidal tract deep to it, are heavily represented on slices SM and SM + 1. When there was superior extension with a C/P lesion site, a large lesion was present in the PVWM-corona radiata lateral to the body of the left lateral ventricle on slice SM or SM + 1. These large lesions ranged in size

from 700 to 1,400 pixels (2.6 × 2.6 to 3.7 × 3.7 cm). There was greater than 10% mean tissue damage in the left hemisphere at slices SM and SM + 1.

The term "C/P with posterior extension" is used in this article to describe C/P lesion areas that extended posteriorly across the auditory radiations in the temporal isthmus as described by Nielson,²⁰ originally in 1936. The auditory radiations are present at CT scan slice B/W, inferior to the Sylvian fissure and superior to the temporal horn, where these radiations ascend from the medial geniculate body to Heschl's gyrus and Wernicke's area.¹⁶ This is shown schematically in Fig 1.

Nine cases are given in Tables 1 and 2. Only five cases are detailed. Because small differences in subcortical lesion extension on the CT scan (a few millimeters in one direction or another) were associated with large differences in language behavior, each CT scan is detailed. Following the case reports of each syndrome, a summary of that syndrome is presented.

REPORT OF CASES C/P With Anterior-Superior Lesion Extension

CASE 1.—The medical history of a 53-year-old right-handed man before stroke

onset, in January 1976, was unremarkable.

The CT scan obtained one day after the patient's stroke (Fig 2, top) showed a large low-density area consistent with occlusive-vascular etiology in the region of the left internal capsule and basal ganglia (Fig 2, slice B/W). The CT scan at 13 months after the stroke (Fig 2, bottom) disclosed at slice B/W a much smaller low-density focal area that was limited to the left putamen and part of the anterior limb, internal capsule, PVWM deep to Broca's area, and a small patchy lesion in the posterior limb of the internal capsule. Additional superior lesion extension was present at PVWM-corona radiata deep to the precentral gyrus area, representing the face at slices SM and SM + 1. The mean percent of tissue damage in the left hemisphere at slices SM and SM + 1 was 10.2%. Lesion was present in the caudate nucleus at slices W, SM, and SM + 1, but not at slice B or B/W.

The initial description of the aphasia was incomplete, but the patient apparently had some difficulty in understanding written and spoken commands. At two months after the stroke, his comprehension was good, and testing with the BDAE (Table 2) showed speech output to be grammatical but slow, with a severe dysarthria. His description of the BDAE "cookie theft

picture" was as follows: "Well, here the wind coming *du* the curtains. . . Here the boy going in *coodie* jar getting *coodie* out." At 13 months after the stroke, the grammatical but slow dysarthric speech output continued, and occasional verbal paraphasias were present, ie, "The stool is *kilking-tilting*, and he's going into the cookie *department*. . . The two cups and a platter are to the end, having been dried."

The BDAE rating scale profile of spontaneous speech characteristics for this patient at 13 months after the stroke was plotted against the BDAE Broca's aphasia profile as shown in Fig 3. Only two features on this profile were compatible with Broca's aphasia, impaired articulatory agility (2/7), and normal comprehension. The other features (melodic line, phrase length, and grammatical form) were not. The impaired articulatory agility rating in spontaneous speech was compatible with a poor verbal agility score of only 8/14 in the

timed Verbal Oral Agility task on the BDAE (rapid repetition of the same word for 5 s, eg, caterpillar, caterpillar, etc).

Although repetition of single words improved greatly from two to 13 months after the stroke, impaired repetition of low-probability sentences persisted up to 13 months after the stroke. Most errors, however, were caused by poor articulation, eg, "I *shopped* [stopped] at his front door and rang the bell," and "The Chinese fan had a rare *enweld* [emerald]." These repetitions were slowly produced in a word-by-word manner.

The patient's silent-reading comprehension score was only 3/10 for sentences and paragraphs at nine months after the stroke. With his right hand, he wrote sentences with paragraphic errors, as follows: "Boy and girls are *keeping* a cookie. Woman is washing a dish." He had a mild buccofacial apraxia, but there was no left-limb apraxia. Table 2 gives a summary of

more BDAE testing at two and 13 months after the stroke.

The patient was able to live at home and received outpatient speech therapy. Eventually, the paresis of the right upper extremity resolved sufficiently to allow him to drive a specially adapted car. He was unable to return to work at his law practice. He died three years later after a left pontine infarction. Permission for an autopsy was denied.

CASE 2.—Tables 1 and 2 give a summary of neurologic and aphasia testing for this 64-year-old woman. This patient was initially mute; however, at one month after onset, her speech was grammatical and slow, with a severe dysarthria. Repetition errors in phrase repetition were primarily articulatory distortion errors and word omissions, as follows: "Limes are *tour* [sour]"; "The barn *wallow* [swallow] . . . [omitted remainder (captured a plump worm)]"; and "The spy *led* [fled] to

Table 2.—Boston Diagnostic Aphasia Examination (BDAE) Test Scores for Three C/P Aphasia Groups*

	C/P With Anterior-Superior Extension			C/P With Posterior Extension			C/P With Anterior-Superior and Posterior Extension		
	1	2	3	4	5	6	7	8	9
Testing, mo after stroke	2/13	1/6	1/12	1	3/39	31/60	15	3	2/66
Spontaneous Speech	Grammatical	Grammatical	Grammatical	Fluent	Fluent	Fluent	No speech or only stereotyped monosyllables		
No. of Words per Phrase (7)	4/7	4/6	4/6	7	4/7	4/5	1	1	1/2
Articulatory Agility (7)	2.5/2	2/3	4/4	6	5.5/6	4.5/5	1	1	1/1
Grammatical Form (7)	5/7	2/5	4/5	7	5/5	4.5/5	1	1	1/2
Timed Verbal Oral Agility (14)	.../8	6/4	7/8	14	11/14	9/11	...	0	.../3
Timed Nonverbal Oral Agility (12)	11/10	.../1	.../5	6	6/7	9/8	9/10
Comprehension BDAE Z score (+1)	+0.5/+1.0	+0.5/+0.5	+0.2/+0.8	-0.6	-0.7/+0.3	-0.3/-0.6	-1.05	-1.7	-0.2/+0.3
Body Parts (20)	18/20	17/18	13/20	13.5	9.5/17	10/8	11	7	16/13.5
Complex Ideational Material (12)	6/10	9/8	6/9	1	4/4	4/2	0	2	5/8
Repetition Words (10)	4/9	8/9	10/9	9	10/10	9/10	0	0	2/8
High-Probability Phrases (8)	7/8	4/8	5/8	4	5/6	3/4	0	0	1/1
Low-Probability Phrases (8)	2/3	1/3	2/5	4	4/5	4/1	0	0	1/1
Naming Pictures (105)	.../102	30/85	37/91	61	54/97	61/68	0	0	9/66
Objects (18)	.../18	6/17	9/15	9	6/12	5/6	0	0	6/2
Letters (18)	.../18	0/11	6/16	15	12/18	18/15	0	0	3/14
Silent Reading Sentence Comprehension (10)	.../3	4/7	6/9	3	6/7	5/6	0	2	5/2
Writing narrative sentences	Incomplete but relevant sentences	No relevant writing	No relevant writing	Single words, small groups	Incomplete but relevant sentences	Incomplete but relevant sentences	No relevant writing		
Praxis Buccofacial apraxia	Mild	Moderate	Mild	None	Mild	None	Severe	Very severe	Severe
Left-limb apraxia	None	Moderate	None	Mild	Moderate	Mild	Severe	Severe	Severe

*C/P indicates capsular/putaminal; numbers in parentheses are highest possible score for each item.

Greece." Like patient 1, her sentence repetition was slow and word by word. Visual confrontation naming was remarkable in that, at each test date, she performed better at naming objects than letters.

CASE 3.—Tables 1 and 2 give a summary of neurologic and aphasia testing for this 45-year-old man. Errors in phrase repetition included the following articulatory distortions and word omissions at one month after stroke: "Doon . . . down to earth" for "Down to earth" and "The swallow *catchered* a barn swallow" for "The barn swallow captured a plump worm"; and at 12 months after stroke: "The spy . . . the spy *led* to Greece" for "The spy fled to Greece."

Visual confrontation naming was similar in this case to case 2, in that at one month after the stroke, there was better ability to name objects than letters. This patient was tested for comprehension of grammatical sentences at three years after stroke. At that time, the following findings were noted: (1) He had excellent comprehension for long sentences that required pointing to a substantive, ie, when asked, "Would it be possible for you to demonstrate to me an apparatus utilized for the purpose of communication with those at a great distance from one's present location?" the patient pointed immediately to the telephone. (2) He had no comprehension for short sentences that were more grammatically complex, ie, when asked, "Is your mother's

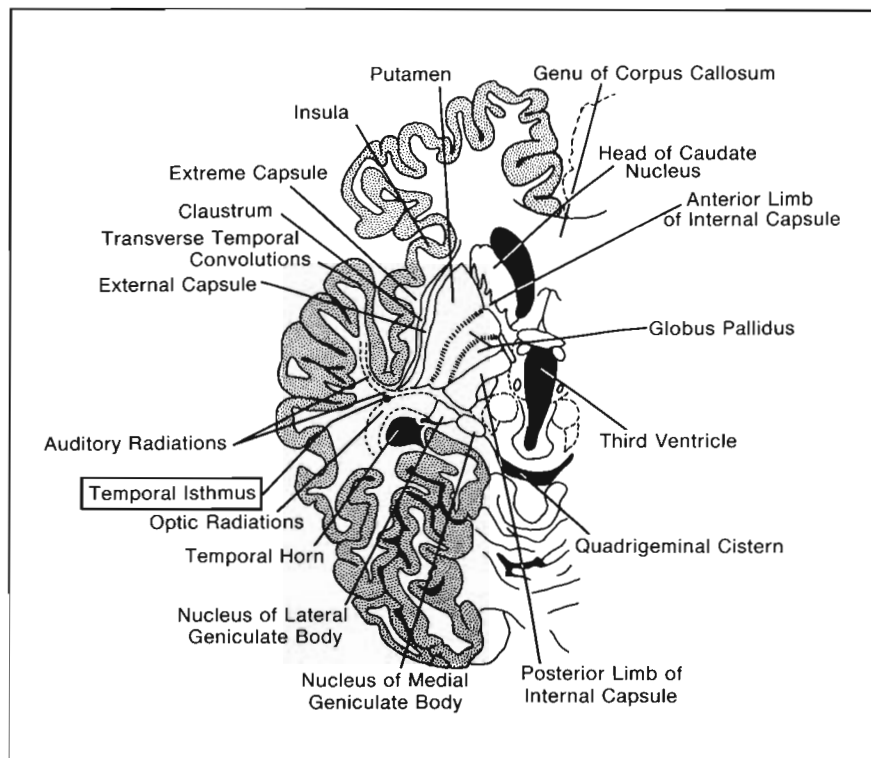


Fig 1.—Schematic drawing of computed tomographic scan slice B/W (left hemisphere) shows location of deep structures and auditory radiations within anterior portion of temporal isthmus.

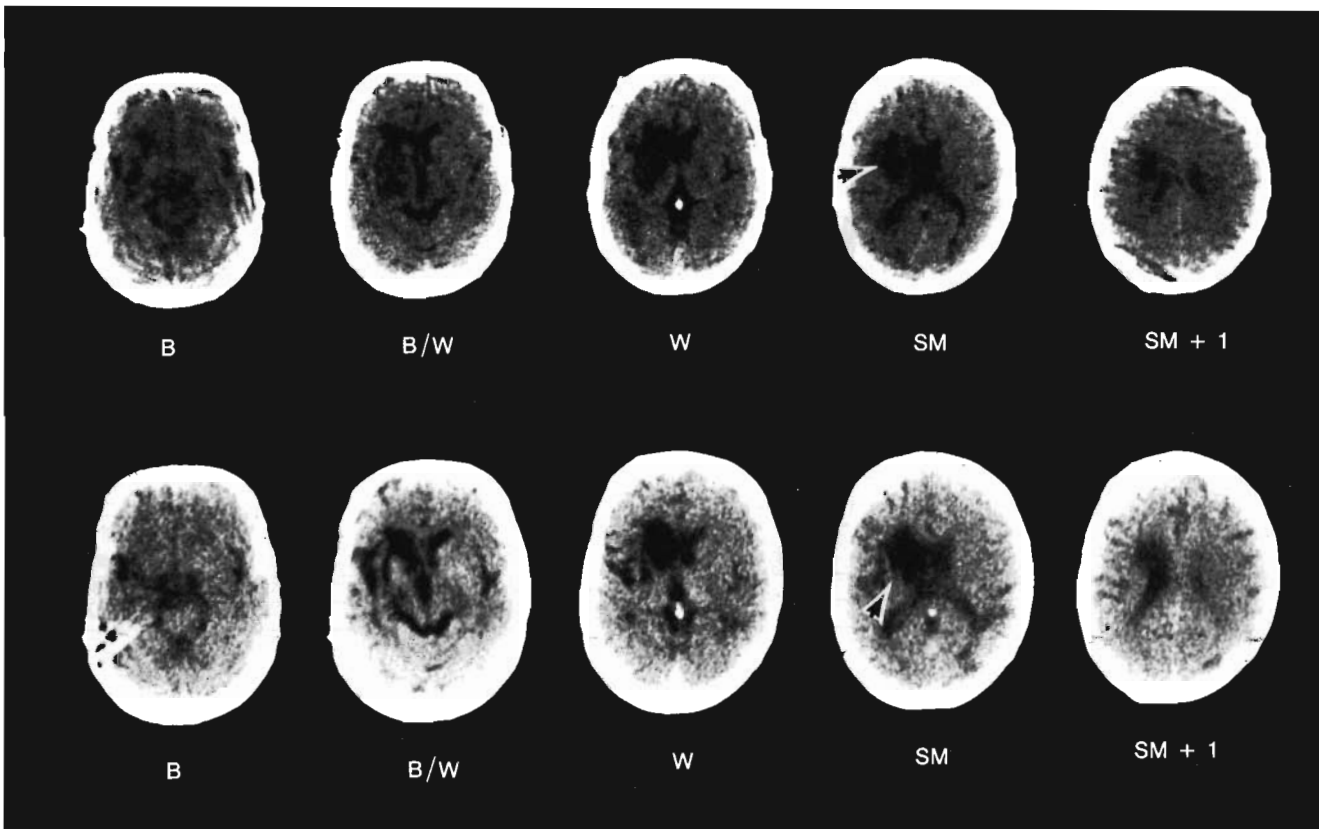


Fig 2.—Computed tomographic scans (case 1) done one day after stroke (top) and 13 months after stroke (bottom). Subcortical lesion site with occlusive-vascular etiology is capsular putaminal with anterior-superior lesion extension. Large lesion at slice SM extends laterally from ventricle, at least halfway toward cortex (arrows).

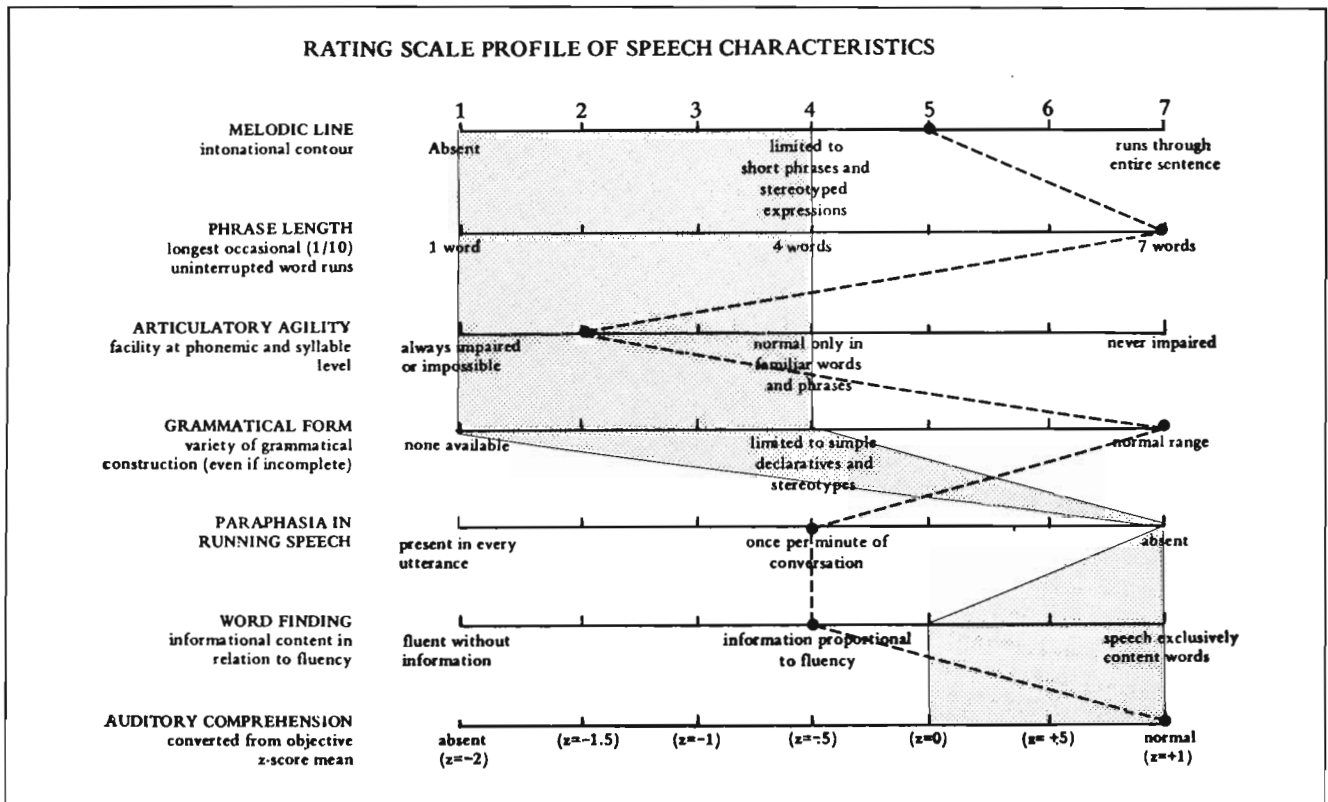


Fig 3.—Boston Diagnostic Aphasia Examination rating scale profile of speech characteristics. Characteristics typical of Broca's aphasia are shown in shaded area. Characteristics of case 1 (capsular/putaminal with anterior-superior lesion extension) are shown with broken line (13 months after stroke). Note that impaired articulatory agility and good comprehension are the only areas of overlap in scores.

brother a man or a woman?" he was perplexed and denied he could do the task. When told, "The lion was killed by the tiger. Which animal died?" he had no response. When shown a pencil and a pen, and asked to touch the pencil with the pen or the pen with the pencil, he was again perplexed and even after multiple demonstrations, could not do the task. Hence, in this case of subcortical C/P aphasia with anterior-superior lesion extension, there was great disparity in semantic vs syntactic comprehension ability.

The etiology was occlusive-vascular in all three of these cases of C/P aphasia with anterior-superior lesion extension. Each patient had a right hemiparesis, but only one had a right visual field deficit. All the patients were alert from the onset.

The composite CT scan lesion sites for cases 1 through 3 are shown in Fig 4. At slice B/W, each case had a lesion in the putamen and part of the anterior limb of the internal capsule, with anterior extension into PVWM deep to Broca's area and large (greater than 10% left-hemisphere tissue damage) superior extension into PVWM-corona radiata deep to the precentral gyrus area, representing

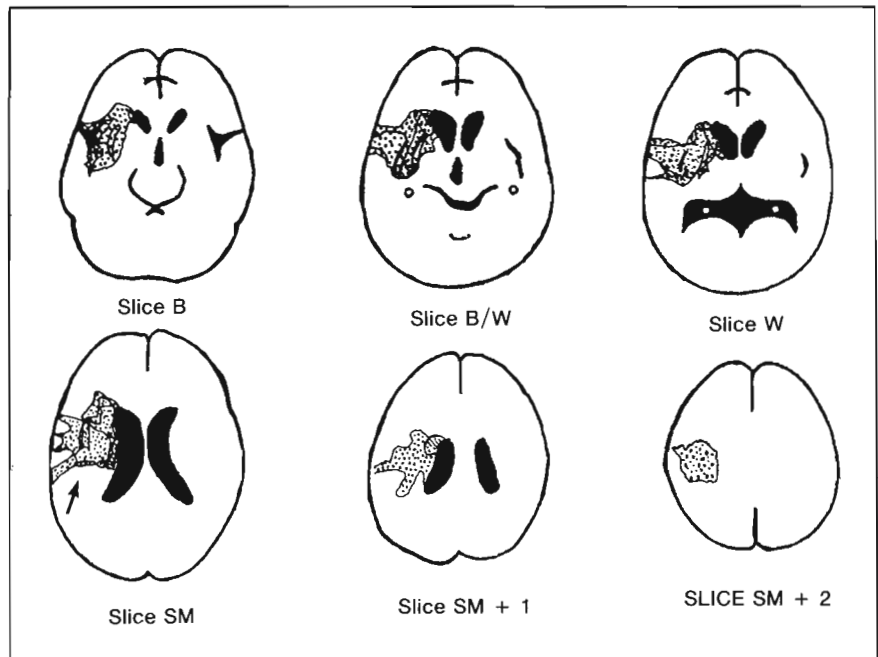


Fig 4.—Composite computed tomographic scan lesion sites for subcortical aphasia (cases 1 through 3) (capsular/putaminal lesion sites with anterior-superior lesion extension). Anterior lesion extension is in periventricular white matter (PVWM) deep to Broca's area at slice B/W; large superior lesion extension is in PVWM—corona radiata deep to the precentral gyrus area, representing

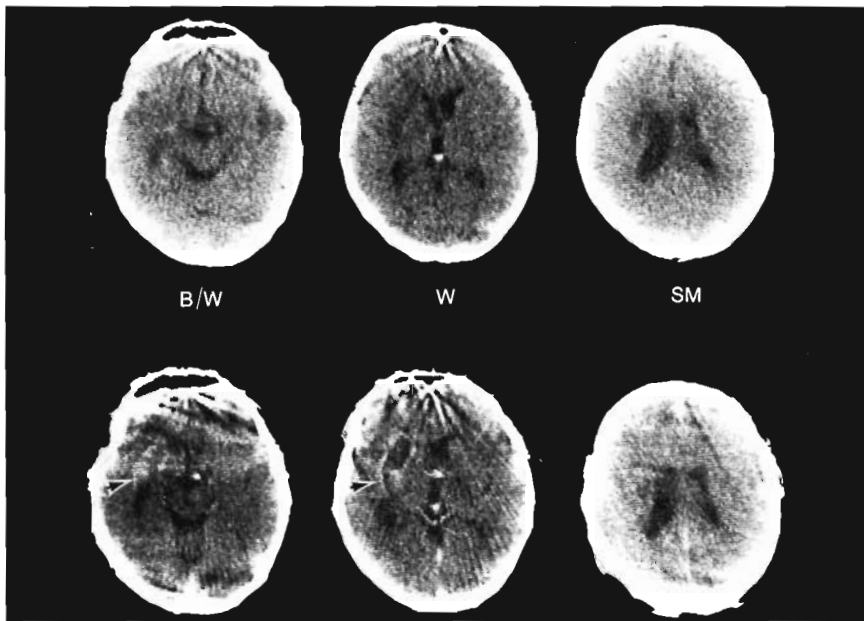


Fig 5.—Computed tomographic scans (case 4) done four months after stroke without contrast enhancement (top) and with contrast enhancement (bottom). Subcortical lesion site with hemorrhagic etiology is capsular/putaminal with posterior extension. Arrows indicate posterior lesion extension across auditory radiations in temporal isthmus. Note that although scan was done at near-horizontal angle, location of temporal isthmus is still anterior to temporal horn on slice B/W and anterior to atrium on slice W.

the lower part of the face at slice SM and/or SM+1. Lesion was also present in varying amounts in the posterior limb, internal capsule, globus pallidus (mostly spared), parts of the caudate nucleus, and the area of the external capsule, claustrum, extreme capsule, and insula.

Examination of the lesion sites showed that the probable source of the hemiparesis in each of these cases was the large PVWM-corona radiata lesion at slice SM. To gross visual inspection, these large lesions in the PVWM-corona radiata extended laterally from the body of the lateral ventricle, at least *halfway* toward the cortex.

The predominant aphasia pattern for these three cases of subcortical aphasia with C/P lesions and anterior-superior extension was that of good semantic comprehension (but poor syntactic comprehension as tested in case 3) and grammatical but slow dysarthric speech output; one patient (case 2) was initially mute. The impaired BDAE articulatory agility scores of only 2 to 4/7 in spontaneous

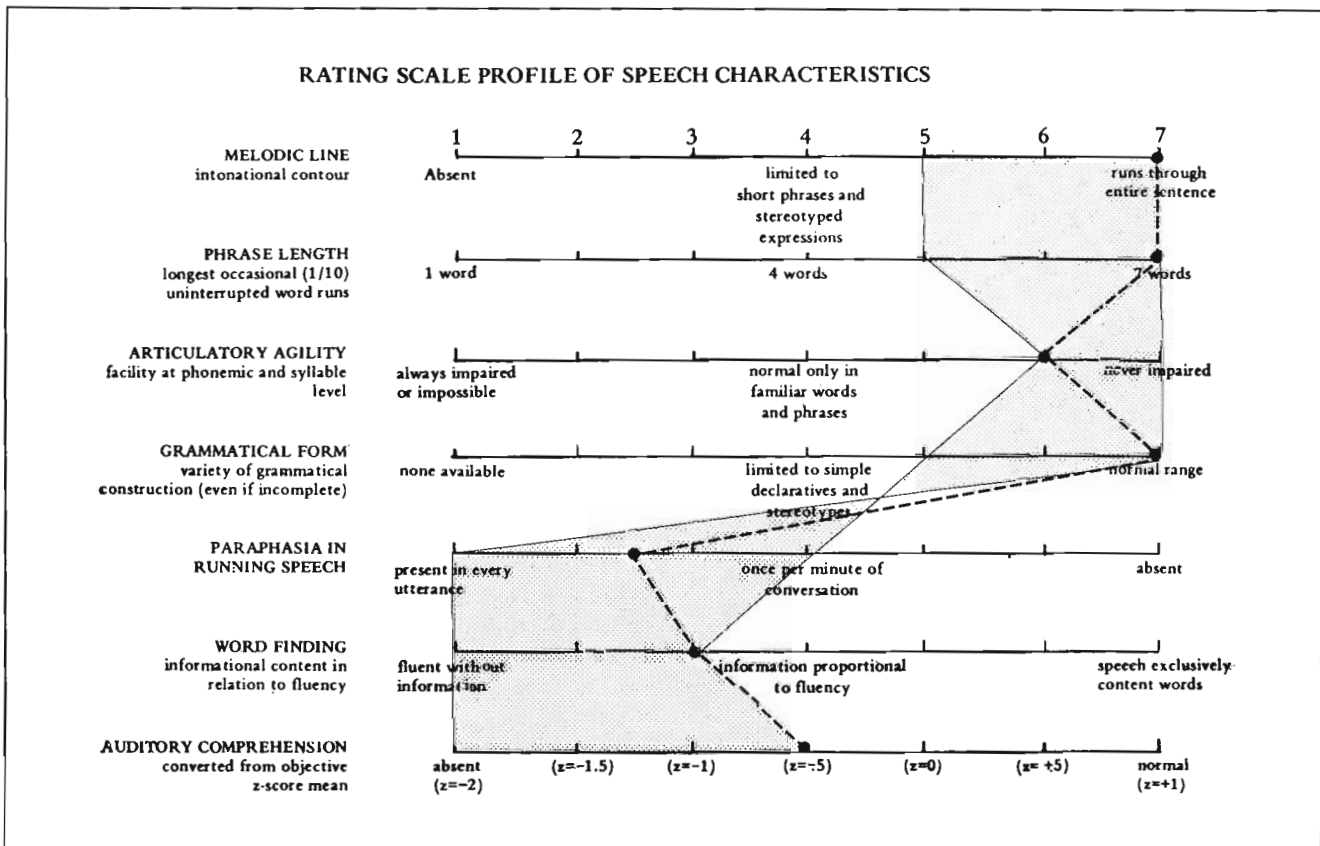


Fig 6.—Boston Diagnostic Aphasia Examination rating scale profile of speech characteristics. Characteristics typical of Wernicke's aphasia are shown in shaded area. Characteristics of case 4 (capsular/putaminal with posterior lesion extension) are shown with broken line (one month after stroke). Note that all characteristics, including poor comprehension, overlap in scores.

speech were compatible with the poor timed Verbal Oral Agility scores of only 4 to 8/14. Repetition was impaired primarily for low-probability sentences, and errors were severe articulatory distortions and word omissions. Picture naming was impaired, with better naming of *objects* than letters. Silent reading and writing were impaired. Although each patient had some buccofacial apraxia, two of the three patients had no left-limb apraxia.

The neuroanatomic pathways underlying the language behavior observed in these patients are not well understood at this time. We believe that the lasting slow dysarthric component of the speech observed in cases 1 through 3 has three possible anatomic foundations: (1) the anterior PVWM lesions deep to Broca's area at slice B/W, (2) the large lesions of the superior PVWM-corona radiata deep to the face, lips, and tongue area of the precentral gyrus at slice SM, or (3) various combinations of lesion sites, ie, No. 1 plus No. 2 or these plus putaminal lesion sites. Patients with only small white-matter lesions deep to Broca's area, but not as far medially as PVWM, are often classified as transcortical motor aphasics and have good articulation.^{13,14} The preserved grammatical form that was present in the speech output may have been associated with the intact Broca's area.

Lesion size could be a factor in these three cases in which true aphasia, not just severe dysarthria, was present. Fisher²¹ has recently reported a series of capsular infarcts that were studied at autopsy. In three cases in which right hemiparesis and slurred speech (not aphasia) were present, the lesion sizes ranged from less than 0.5 to 2.5 cm vertically. The largest lesion size in the anterior-posterior plane was 2 cm; in the transverse plane, it was 1.2 cm. Those lesions observed at autopsy were much smaller than the lesions observed in the present study, on CT scans.

In summary, the cases of subcortical aphasia with C/P lesion sites and anterior-superior extension did not completely resemble any traditional aphasia syndrome, including Broca's or Wernicke's aphasia, in neurologic findings, CT scan lesion sites, or language behavior. These cases were similar to Broca's aphasia in that they had a right hemiparesis (plegia), impaired articulatory agility, and good comprehension. They were similar to Wernicke's aphasia in that they had more grammatical speech, with four to six words per phrase length. The pre-

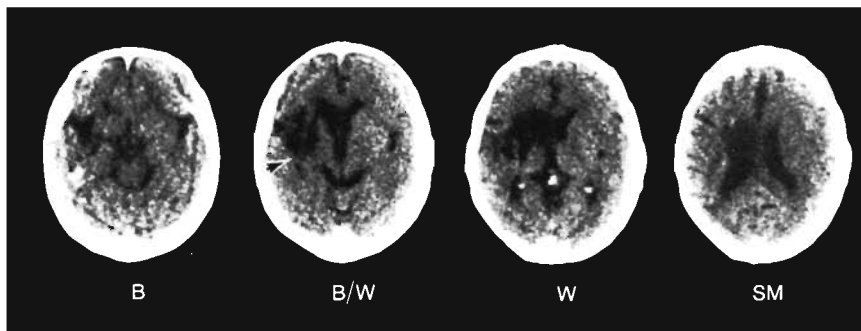


Fig 7.—Computed tomographic scan (case 6) done at 31 months after stroke. Subcortical lesion site is capsular/putaminal with posterior lesion extension (arrow is at temporal isthmus).

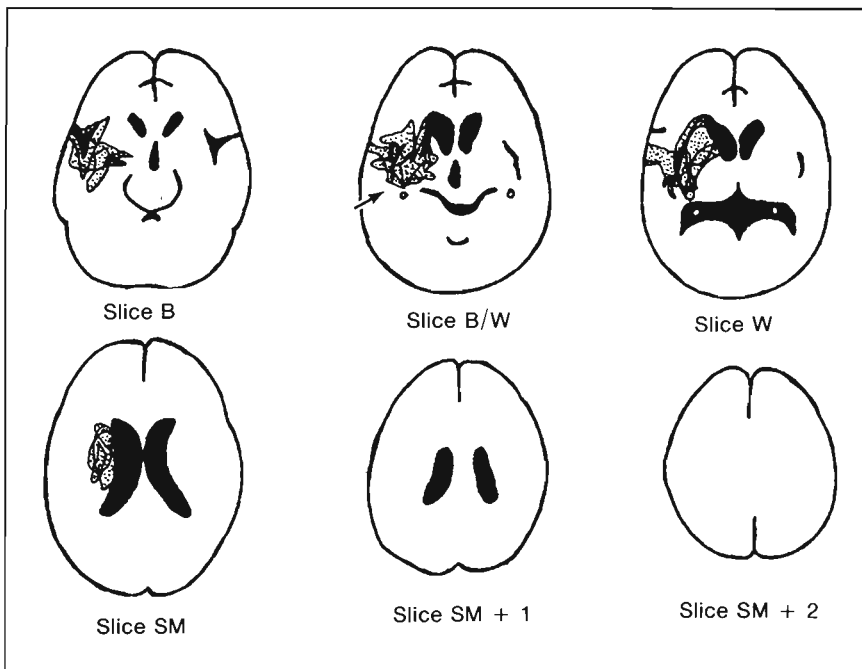


Fig 8.—Composite computed tomographic scan lesion sites for subcortical aphasia (cases 4 through 6) (capsular/putaminal lesion sites with posterior lesion extension). Posterior lesion extension includes auditory radiations in temporal isthmus, anterior to temporal horn at slice B/W (arrow). Small superior lesion extension in periventricular white matter—corona radiata at slice SM extends laterally less than halfway toward cortex from body of lateral ventricle.

served ability of these patients to name objects better than letters was more compatible with Broca's aphasia.²² The good semantic, but poor syntactic, comprehension observed in case 3 was also more compatible with the comprehension ability observed in Broca's aphasia.²³

C/P With Posterior Lesion Extension

Case 4.—A 43-year-old right-handed man with a history of severe labile hypertension and diabetes mellitus suffered an intracerebral hemorrhage that was confirmed by acute CT scan in March 1977.

The CT scan performed four months after the stroke without contrast enhancement (Fig 5, top) showed, at slice W, a lesion in the area of the left putamen, part

of the anterior limb, internal capsule, and PVWM in the frontal lobe. Lesion was also present in the PVWM deep to the precentral gyrus at slice SM. The percent tissue damage in the left hemisphere at this slice was only 5.8%. The CT scan performed with contrast enhancement (Fig 5, bottom) showed enhancement of the lesion site as mentioned previously at slices B/W and W, as well as lesion extension across the temporal isthmus (arrows in Fig 5).

At one month after the stroke, the patient had a moderate comprehension deficit, and his speech output was described as fluent with multiple verbal paraphasias and neologisms. There was no dysarthria or impairment of articulatory agility, as demonstrated by the patient's description of the cookie theft picture at one month after the stroke: "It's a girl... a short girl with long hair... has a *tenti*

service. The boy is *scouting* the jar of cookies. He's *looting the bowl*. The faucet is off... the faucet is on."

The rating scale profile of speech characteristics for this case was similar to the profile for Wernicke's aphasia (Fig 6). The good BDAE articulatory agility rating of 6/7 in spontaneous speech was compatible with the perfect score of 14/14 in the timed Verbal Oral Agility task. However, this same patient had a poor score of only 6/12 in the timed Nonverbal Oral Agility task (rapid repetition of opening and closing the mouth or moving the tongue in and out, for 5 s). This good performance on the timed Verbal Oral Agility task and poor performance on the timed Nonverbal Oral Agility task seems to be unique. It is a combination not often observed in patients with Wernicke's aphasia. In addition, this patient differed from most patients with typical Wernicke's aphasia in that he had a dense right hemiparesis.

Although the patient's ability to repeat single words was good at one month after the stroke (9/10 correct), sentence repetition was impaired; most response errors were paraphasic, with extended English jargon, as follows: for "They heard him speak on the radio last night," he said "They heard him speak on the radio with *voices they learned from*," and for "The lawyer's closing argument convinced him," "The lawyer's closing argument *consisted of his words*."

Visual confrontation naming was remarkable in that a greater number of letters than objects were correctly named.

The patient's silent-reading comprehension score was only 3/10 for sentences. His writing (with his left hand) was limited to isolated words or small groupings. At four months after the stroke while being administered another test, he wrote "The comb is *fare*." Table 2 gives the other BDAE scores for this patient.

The patient had no buccofacial apraxia, but he had a mild left-limb apraxia on verbal command only, not imitation. Non-representational praxis testing was unimpaired.

The patient was discharged four months after the stroke to his home. At discharge, he was described as still aphasic but "much improved" in all language modalities, especially comprehension. The patient, a teacher, was unable to resume teaching and died of a second stroke one year eight months after the first stroke. Permission for an autopsy was denied.

Case 5.—Tables 1 and 2 give a summary of neurologic and aphasia testing for this 62-year-old man. Although single-word repetition was good, sentence repetition was poor. Errors were primarily verbal paraphasias, eg, "The barn swallow *pampered* [captured] a plump worm," and "The phantom *scored* [soared] across the foggy heath." At 39 months after the stroke, he wrote the following description of the cookie theft picture with his left hand: "Boy is thaken some cooke jar. His sneakers are fallen from the _____. The girl is laughen. Then mama is washing the falls. The water is fallin from the sink."

Case 6.—A 64-year-old right-handed man who was trilingual (English, Chinese, and Russian) had a medical history that was unremarkable except for two transient ischemic attacks approximately three weeks before a stroke in June 1974.

A CT scan performed at 31 months after the stroke (Fig 7) showed, at slice B/W, an infarct in the left putamen and anterior and posterior limbs of the internal capsule, with posterior extension across most of the temporal isthmus. The lesion also included the anterior and posterior limbs, internal capsule at slice W, and a small area of PVWM deep to the precentral gyrus at slice SM. Lesion was present in the caudate nucleus only at slices W and SM. The mean percent tissue damage in the left hemisphere, at slice SM, was only 5.6%. There was mild ventricular dilation, particularly on the left side.

At 60 months after the stroke, the comprehension deficit persisted, and speech output was remarkably unchanged, ie, it was still fluent, but limited in the number of words (five) per longest phrase: "She... uh... very difficult... Mrs is trying to *kry* [dry]... no... I will see... I have to... I don't know... this little girl... little girl is trying to... boy... and this um, cookie jar... I forgot this... mother... this is mother of..."

Although single-word repetition was good, sentence repetition was poor. Errors were primarily literal and verbal paraphasias and extended English jargon, as follows: for "The phantom soared across the foggy heath," he said "The phantom *crossed across the fog*," and for "The spy fled to Greece," "The spy *spled to Greece*."

At 31 months after the stroke, the patient wrote the following sentence to describe the cookie theft picture with his left hand: "The girl ask cookie the boy brig." The word order in this sentence was incorrect for both Chinese and Russian, as well as English. At 60 months after the stroke, he was unable to do any writing. His wife reported that he was also aphasic for Chinese, although they had not spoken Chinese for many years before the stroke. Although the patient used his wheelchair most of the time, he and his wife had recently completed a trip to Thailand before follow-up testing at five years after the stroke.

The etiology was occlusive-vascular in cases 5 and 6 and intracerebral hemorrhage in case 4. The two patients with occlusive-vascular lesions were alert throughout, but the patient with the hemorrhage was briefly comatose in the initial stage. Each case had a right hemiparesis (plegia), a mild sensory loss on the right side, and a right visual field deficit.

The composite CT scan lesion sites for cases 4 through 6 are shown in Fig 8. At slice B/W, each case had a lesion in the putamen, anterior limb and part of the posterior limb of the inter-

nal capsule, with posterior extension across most of the auditory radiations in the temporal isthmus. There was only minimal superior extension (less than 10% left-hemisphere tissue damage) at slice SM and none at slice SM+1. The lesion area in the PVWM-corona radiata at slice SM extended less than halfway, laterally, toward the cortex. Lesion was also present in parts of the globus pallidus, caudate nucleus, and in the area of the external capsule, claustrum, extreme capsule, and insula in each case.

It is likely that the lasting right hemiplegia in cases 5 and 6 (Fig 7) was caused by the lesion in the posterior limb of the internal capsule, rather than the higher PVWM-corona radiata lesions, which were small. Case 4 (Fig 5) was reported as having only a right hemiparesis (not hemiplegia), and indeed, most of the posterior limb of the internal capsule was spared. The right visual field deficit, which was observed in each of these three cases, was compatible with lesions in the temporal isthmus in the area where the optic radiations pass through, just posterior to the auditory radiations (Fig 1). Sensory pathways were involved, just medial to the temporal isthmus in the lateral portions of posterior limb of the internal capsule.

The predominant aphasia pattern for these three cases of subcortical aphasia with C/P lesions and posterior extension was one of poor comprehension and rapid fluent speech with paraphasias and extended English jargon. The good articulatory agility scores of 4.5 to 6/7 in spontaneous speech were compatible with the good timed Verbal Oral Agility scores of 9 to 14/14. Performance was poor, however, in the timed Nonverbal Oral Agility task—only 6 or 7/12 in cases 4 and 5 and 8 or 9/12 in case 6. Repetition was impaired on both low- and high-probability sentences. Errors in repetition consisted primarily of verbal paraphasias and extended English jargon. Picture naming was impaired, with consistently better naming of *letters* than objects. Reading and writing were impaired. Although two of the three cases had no buccofacial apraxia, all three cases had a left-limb apraxia.

The neuroanatomic pathways underlying the language behavior observed in these cases are also not well understood at this time. Although each case had damage in Marie's "zone of anarthria,"¹ as well as in parts of the posterior limb of the internal cap-

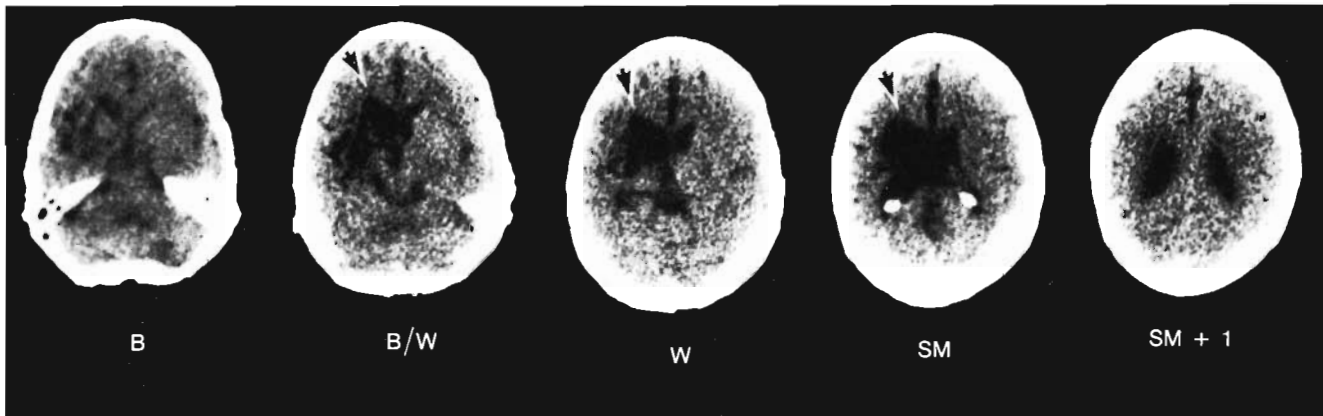


Fig 9.—Computed tomographic scan (case 7) done 15 months after stroke. Subcortical lesion site is capsular-putaminal with both anterior-superior and posterior lesion extension. Frontal lobe lesion in periventricular white-matter extends anteriorly beyond frontal horn, including fibers to genu of corpus callosum (arrows).

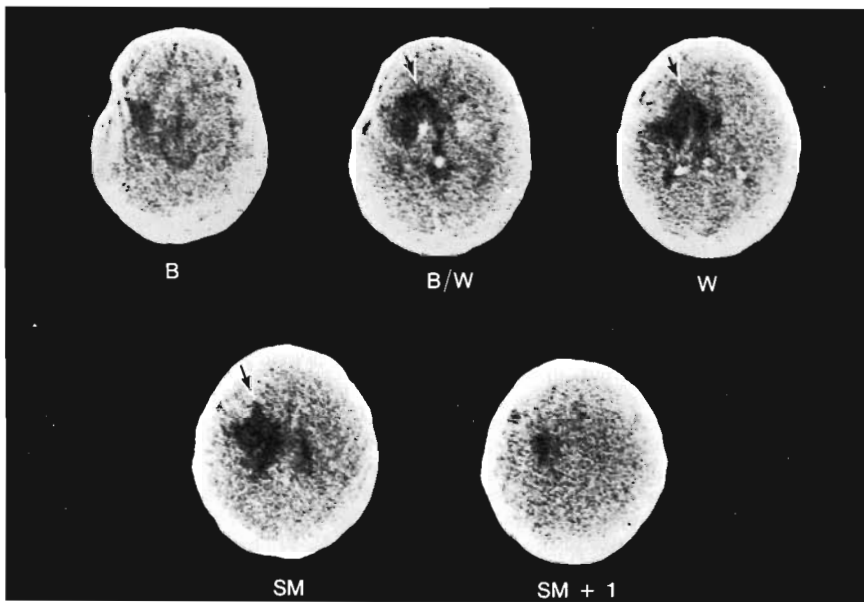


Fig 10.—Computed tomographic scan (case 9) done 26 months after stroke. Subcortical lesion site with occlusive-vascular etiology is capsular/putaminal with both anterior-superior and some posterior extension. Frontal lobe lesion of periventricular white matter extends anteriorly beyond frontal horn, including fibers leading to genu of corpus callosum (arrows).

sule, as described in Fisher's dysarthria cases,²¹ none of them was dysarthric at any stage in the illness. It is possible that the slow dysarthria observed in cases 1 through 3 in this study was caused primarily by larger PVWM lesions deep to the precentral gyrus area, representing the face, lips, and tongue at slice SM, and cases 4 through 6 did not have large enough lesions in this area to produce slow dysarthria.

Future studies with more cases in each category should help define more accurately the structures or combination of structures associated with the lasting slow dysarthria component.

We are not certain of the mecha-

nism of the comprehension deficit observed in these three cases of C/P aphasia with posterior lesion extension. In 1936, Nielsen²⁰ suggested that lesions extending across the temporal isthmus would impair comprehension by damaging the auditory radiations.

It is believed that the auditory fibers in the left temporal isthmus are primarily ipsilateral ascending fibers from the left medial geniculate body.¹⁶ Lasting comprehension deficits, however, probably require damage to the afferent fibers from the contralateral (right) temporal lobe as well. Hence, it is possible that these lesions in the left temporal isthmus were interrupting both ipsilateral and some contralater-

al auditory fibers. Future cases with this posterior lesion extension should be tested with both dichotic listening and cortical auditory evoked potentials to learn more about the auditory pathways involved in these cases.

In summary, the cases of subcortical aphasia with C/P lesion sites and posterior extension did not completely resemble any traditional aphasia syndrome, including Broca's or Wernicke's aphasia, in neurologic findings, CT scan lesion sites, or language behavior. These cases were similar to Broca's aphasia only in that they had a right hemiplegia (or paresis). They were similar to Wernicke's aphasia in that they had a comprehension deficit and fluent paraphasic speech. The preserved ability of these patients to name *letters* better than objects was more compatible with Wernicke's aphasia.²² The presence of a right hemiplegia and the obvious disparity in the timed Verbal and Nonverbal Oral Agility scores made these cases different from most cases of Wernicke's aphasia.

C/P With Both Anterior-Superior and Posterior Lesion Extension

Case 7.—A 64-year-old right-handed man had a history of coronary artery disease and two myocardial infarctions two years before a stroke in December 1975.

The CT scan obtained 15 months after the stroke (Fig 9) showed, at slice B/W, an infarct in the left insular area, including the extreme capsule, claustrum, external capsule, putamen, globus pallidus, and anterior and posterior limbs of the internal capsule with posterior extension across the entire temporal isthmus all the way to the left temporal horn. At the same slice, there was anterior extension to the PVWM deep to Broca's area. This anterior extension of PVWM continued *beyond* the anterior

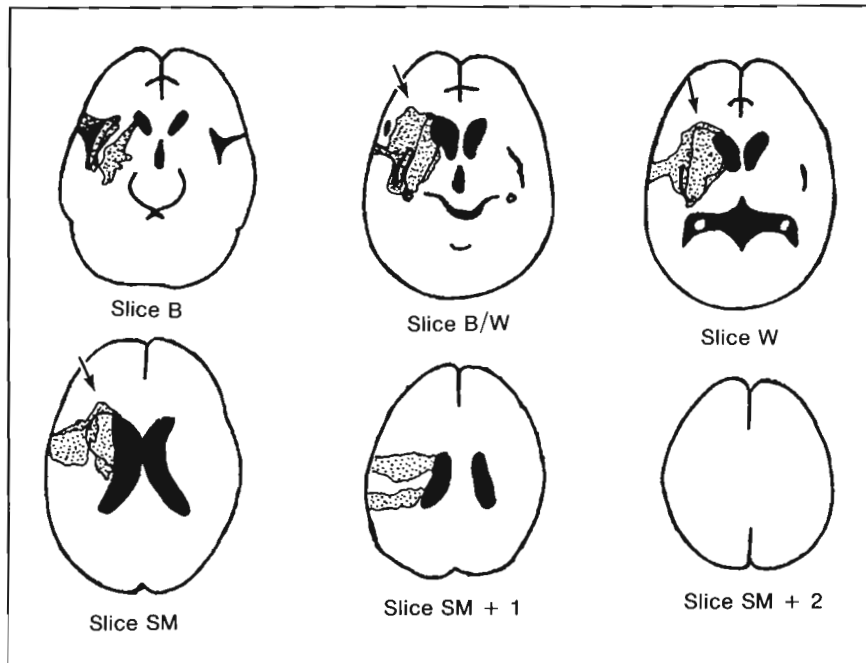


Fig 11.—Composite computed tomographic scan lesion sites for subcortical aphasia (cases 7 and 8) (capsular/putaminal lesion sites with both anterior-superior and posterior extension). Anterior lesion extension is not only in periventricular white matter (PVWM) deep to Broca's area at slice B/W, but continues anteriorly, beyond frontal horn (arrows), probably interrupting Broca's area connections across genu of corpus callosum; large superior lesion extension is in PVWM—corona radiata at slice SM and extends laterally at least halfway toward cortex from body of lateral ventricle; Posterior lesion extension includes auditory radiations in temporal isthmus anterior to temporal horn at slice B/W.

border of the left frontal horn (Fig 9) and included fibers that led to the genu of the corpus callosum (Fig 1). There was a large superior extension into the PVWM—corona radiata deep to precentral and postcentral gyri at slice SM. The mean percent tissue damage in the left hemisphere at slices SM and SM + 1 was 10.6%.

Initially, the patient had a severe comprehension deficit and could utter only "garbled speech sounds." The severe comprehension deficit persisted at 15 months after the stroke, and there was no speech output or only stereotyped monosyllables at that time, eg, "guh . . . dee, guh . . . dee." He had severely impaired articulatory agility, which was rated 1/7 for spontaneous speech. He was unable to perform the timed Verbal and Nonverbal Oral Agility tasks. He could not repeat single words or count. When singing "Happy Birthday," the melody was adequate, but the words were mostly unintelligible. A severe buccofacial apraxia was present. His condition was classified as global aphasia.

The patient was discharged one month after the stroke to his home where he spent most of his time in a wheelchair. Speech therapy sessions were unsuccessful largely because of poor cooperation from the patient. He died three years later after a second stroke. Permission for an autopsy was denied.

Case 8.—Tables 1 and 2 give a summary of neurologic and aphasia testing for this 59-year-old man. This patient was mute for the first three weeks. After that time,

there was little speech output, limited to stereotyped monosyllables, eg, "shizus trai us . . . waz, waz, wass . . ." His condition was classified as global aphasia. The patient was discharged to his home five months after the stroke. Intensive speech therapy, including Melodic Intonation Therapy,^{24,25} was unsuccessful in this case.

Case 9.—A 68-year-old right-handed man had no history of hypertension or cardiovascular disease before a stroke in January 1974. Bilateral carotid bruits were present at the hospital admission.

The CT scan performed at 26 months after the stroke (Fig 10) showed, at slice B/W, an infarct in the left insular area, including the putamen, anterior and posterior limbs of the internal capsule with anterior extension (PVWM deep to Broca's area), and only partial (more medial) posterior extension in the area of the temporal isthmus. At slices B/W, W, and SM, the PVWM lesion extended beyond the anterior border of the left frontal horn to include fibers that led to the genu of the corpus callosum (Fig 10). The caudate nucleus was involved at slices B/W, W, and SM. There was a mild dilation of the left lateral ventricle.

The aphasia in this case seemed to be more "mixed" than global. The patient was tested with the BDAE two months after the stroke at which time he showed only a mild-moderate comprehension deficit, but severely limited speech output. His description of the cookie theft picture consisted mostly of perseverated repetitions

of the name "Theodore, Theodore," and "kougry kruk" for cookie jar and the exclamation "off he goes!" Response errors were primarily severe articulatory distortions, ie, purple was repeated "korgil," and W, "dellowgut." The number 1776 was repeated "1445." Sentence repetition was also poor. Errors were either articulatory distortions or extended English jargon as follows: for "You know how," he said "You take a fine," and for "Go ahead and do it if possible," "Go ahead and do it if file." He was able to count and to sing "Happy Birthday."

Thus, although most language deficits in this case were severe, comprehension was partially spared, eg, only 0.2 SD below the mean for aphasics (two months after the stroke).

The patient was discharged to his home three months after the stroke. He received intensive speech therapy during the next year, and although his speech output remained limited, his language comprehension improved, ie, the Token Test scores²⁶ improved from 53% at two months after the stroke to 65% at six months.

The patient was again seen at 66 months after the stroke, and the aphasia was essentially unchanged. He continued to have a dense right hemiplegia that required the use of a wheelchair most of the time. He was cheerful and cooperative, as he had been since the stroke onset.

The etiology was occlusive-vascular in cases 7 through 9. Two patients were alert from onset, and the third patient was only initially somnolent. Each case had a right hemiplegia, two of three cases had a right sensory loss, and all three cases had a right visual field deficit.

The composite CT scan lesion sites for cases 7 and 8 are shown in Fig 11. At slice B/W, each case had a lesion that was centered in the putamen, globus pallidus, and anterior and posterior limb of the internal capsule. The lesion extended anteriorly in the PVWM deep to Broca's area, including fibers that lead to the genu of the corpus callosum beyond the frontal horn, and posteriorly, completely across the temporal isthmus. Each case also had a large superior extension (greater than 10% left-hemisphere tissue damage) to the PVWM—corona radiata at slice SM. Case 9 was not included in this composite drawing because although this case had similar anterior and superior extension to that observed in cases 7 and 8, the posterior lesion extension at the temporal isthmus was more medial and not as complete. Lesion was also present in part of the caudate nucleus and in the area of the external capsule, claustrum, extreme capsule, and insula in each case.

Cases 7 and 9 (Fig 9 and 10) clearly had lesion in the posterior limb, inter-

nal capsule, as well as large PVWM-corona radiata lesion at slice SM; hence, their right hemiplegia and right hemisensory loss could be associated with either posterior limb, internal capsule lesions, and/or higher PVWM-corona radiata lesion sites deep to precentral and postcentral gyri. The right visual field deficit in these cases was associated with the lesions in the area of the temporal isthmus at slice B/W.

The severely limited speech output of cases 7 through 9 did not differ from other cases of global aphasia in which there were large combined cortical and subcortical lesions demonstrated on CT scans.^{14,27,28} Indeed, the severely limited speech output in these three subcortical cases was probably related to isolation of Broca's area because of damage to afferent pathways (lesions in the temporal isthmus and extreme capsule) and to efferent pathways (anterior limb of the internal capsule, and genu of corpus callosum). The severely limited speech output is similar to the case reported by Bonhoeffer in 1914²⁹; this patient had lesions in the anterior limb of the internal capsule, as well as lateral to the genu of the corpus callosum.³⁰ Thus, Broca's cortical area and the surrounding U fibers were still intact, but there was no remaining pathway available for left-hemisphere speech output. The cases in our study are also similar to the single case of global aphasia, which was associated with large putaminal hemorrhage, reported by Hier et al.³ In that case, the hemorrhage extended both anteriorly, beyond the frontal horn in PVWM, including fibers that led to the genu of the corpus callosum, as well as posteriorly across the temporal isthmus. Their patient remained globally aphasic with a right hemiplegia six months later, despite early evacuation of the hematoma. The cases of subcortical global aphasia in our study are also similar to a subcortical case recently reported by Mazzocchi and Vignolo³¹ in which a small basal ganglia lesion shown on CT scan had anterior extension beyond the frontal horn and posterior extension across the temporal isthmus. The degree of increased anterior lesion extension into the fibers that lead to the genu of the corpus callosum in the present cases of C/P global aphasia is well visualized when composite Fig 11 (global C/P) and Fig 4 (C/P with anterior-superior lesion extension) are compared. We believe that it is the combination of the increased degree of anterior, posterior, and/or lateral

lesion extension that results in the severely limited speech output observed in these cases.

The neuroanatomic pathways underlying the comprehension deficits observed in cases 7 and 8 deserve further comment. As in cases 4 through 6, the comprehension deficit probably was related to a complete lesion in the temporal isthmus of the ascending auditory radiations from the ipsilateral thalamus and possibly some fibers from the contralateral temporal lobe near that region. Many of the contralateral auditory fibers from the right temporal lobe cross the posterior portion of the corpus callosum and descend lateral to the left atrium before connecting to Wernicke's area.^{32,33} This pathway may be undamaged in these cases; Wernicke's area, itself, appeared to remain intact. Comprehension could potentially be better preserved in these cases of subcortical global aphasia than in other cases of cortical-subcortical global aphasia because of the largely undamaged contralateral auditory pathways and undamaged Wernicke's area. One of the cases of subcortical global aphasia (case 8) in our study was only 1 SD below the mean on the BDAE auditory comprehension Z score at 15 months after a stroke. The three patients who had C/P aphasia with posterior lesion extension only (cases 4 through 6) (Fig 8) did have somewhat better comprehension than the average patients with Wernicke's aphasia. One case even recovered to +0.3 on the BDAE auditory comprehension Z-score profile at nine months after the stroke (case 5). Hence, comprehension deficits secondary to damage in the temporal isthmus may not be as severe as those deficits related to cortical posterior-superior temporal lobe (Wernicke's area) lesions.

In addition to specific differences in the lesion site between cases of subcortical global aphasia cases and of cortical-subcortical global aphasia, there were large differences in the lesion size. The cases of C/P aphasia with both anterior-superior and posterior extension had only 9.2% to 15.6% tissue damage in the left hemisphere at slice B/W, whereas the cases of cortical-subcortical global aphasia from previous studies had a mean of 28.5% tissue damage in the left hemisphere at that same slice.⁴⁴

COMMENT Etiology of Lesions

The vascular pathophysiologic condition that produced these subcortical

lesions is not known with certainty, and we have no postmortem data. The lesion in case 4 was the result of a hypertensive hemorrhage in the distribution of the lenticulostriate branches of the middle cerebral artery. This initial hemorrhage was large, and the patient's initial deficits were more severe, as reported in case 10 by Alexander and LoVerme.¹² Our data in this article reflected the later stable language disorder secondary to a residual cerebral lesion. The lesions in the other eight cases in this study were caused by infarction, and these ischemic lesions were also in the distribution of the lenticulostriate vessels. In several cases, the infarct extended into the deep arterial border zone between the deep cortical perforators of the middle cerebral artery, and the anterior cerebral artery and the lenticulostriate arteries.³⁵ Extension of the infarct in this manner probably accounted for the anterior-superior lesion extension to the deep PVWM-corona radiata. In other cases of subcortical infarction, there was posterior extension of the lesion across the temporal isthmus. This may have been secondary to additional infarction in the deep arterial border zone between the lenticulostriate circulation and the anterior choroidal circulation.³⁵ Infarction in all of the preceding distributions is a known result of internal carotid artery occlusion³⁶; small variations in collateral circulations may produce small differences in lesion size and extent. We have information about the vascular system in only one of the eight cases of occlusive-vascular etiology (case 3). This patient had an occlusion of the internal carotid artery that was shown by arteriography. There are probably other vascular mechanisms that result in subcortical lesions similar to those seen in the patients in our study. At the present time, occlusion of the internal carotid artery seems to be the likeliest vascular pathologic condition.

Lesion Size and Lesion Site as Determinants of Specific Aphasia Syndromes

The lesion size observed with these nine cases of C/P subcortical aphasia ranged from 4.5% to 19.7% tissue damage in the left hemisphere, at slice B/W (approximately 300 to 1,500 pixels or 1.7 × 1.7 to 3.8 × 3.8 cm). Neither the largest lesion at slice B/W (case 3) nor the largest lesion overall (case 3) was associated with the most severe aphasia (case 8); rather, patient 3 had

grammatical speech output with a slow dysarthria and good comprehension but impaired naming, reading, and writing. Conversely, one of the patients with the most severe global aphasia, case 7, had one of the smallest lesions at slice B/W, 9.2% (732 pixels or 2.7 × 2.7 cm). Clearly, it was the lesion *site* rather than the lesion size that was most important in determining language behavior with these cases of C/P aphasia. Lesion size may be a factor in the severity of articulatory impairment. Patients with small PVWM-corona radiata lesions (less than 10% tissue damage in the left hemisphere at slice SM) had better articulatory agility scores (cases 4 through 6) than those patients with more than 10% tissue damage in the left hemisphere at slice SM (cases 1 through 3 and 7 through 9).

Review of Other Subcortical Lesions and Aphasia

Hemorrhages.—Cases in the present study, as a group, differed from most reported cases of aphasia secondary to intracerebral hemorrhage¹² in several important ways: (1) Completely normal sentence repetition was never observed in this study with the C/P cases. (2) The C/P cases with posterior extension displayed good timed Verbal Oral Agility scores, but they had poor timed Nonverbal Oral Agility scores. To our knowledge, this disparity in Verbal-Nonverbal Oral Agility has not been reported in the literature and was not observed in two cases of thalamic aphasia due to hemorrhage that were recently reviewed in our records. (3) The long-term course of recovery was much more unsatisfactory in the occlusive-vascular C/P cases. Despite these differences, there are similarities between the cases of aphasia that occur after subcortical hemorrhage and those cases that occur after subcortical infarction, eg, the similarity between patient 4 and patients 5 and 6 in this report. The lasting language deficits in some cases of subcortical hemorrhage may actually have been caused by structural damage to the surrounding white-matter pathways (extreme capsule, external capsule, internal capsule, deep PVWM, and temporal isthmus). Specific small differences in the final lesion site are presumably as important in determining the lasting language deficits in the cases of hemorrhage as they are in the cases of occlusive-vascular etiology.

Thalamotomy.—The lasting speech

and language disturbances in these cases of C/P occlusive-vascular aphasia were different from the speech disturbances that occur after thalamic stimulation or surgical disruption of the ventrolateral nucleus of the thalamus.¹⁷ Thalamotomy lesions, particularly in the left thalamus, often produced dysarthria, but aphasia was unusual or transient (see Alexander and LoVerme¹² for a more extensive review). The "fast" or racing dysarthria observed in parkinsonian cases is also different from the "slow" dysarthria observed with the cases of subcortical aphasia with C/P lesion sites and anterior-superior lesion extension.

Role of Striatal Damage

The role of the striatum per se alone or in combination with white-matter lesions in these cases of subcortical aphasia is not known. Some investigators have suggested that the entire neocortex projects to the striatum; the putamen primarily receives afferents from the motor cortex, while the caudate nucleus primarily receives afferents from the prefrontal cortex.³⁸ Research with monkeys has shown that similar deficits in behavior on delayed response tasks can be obtained with lesions either in the prefrontal cortex or the caudate nucleus.³⁹ It is not known if a similar relationship exists between the putamen and the motor cortex. The possible relevance of these findings in monkeys to speech and language in humans is not known. One possible parallel is in children with choreoathetoid cerebral palsy who have severe slow dysarthria and language delay. Another possible parallel is in adults with Huntington's disease who have a dysarthria, although no aphasia.

CONCLUSION

This communication has presented three subcortical aphasia syndromes associated with three subcortical C/P lesion site patterns. They have been arbitrarily labeled C/P because the putamen was the only part of the striatum that appeared to be completely involved in all cases. The caudate nucleus appeared to be completely involved in only two of nine cases (cases 8 and 9, two of the three most severe cases).

Future studies that include both CT scan data and pathology reports will be necessary to establish whether lesions in these cases of C/P subcortical aphasia are completely subcortical,

but it is clear that the patterns of language behavior and the patterns of CT scan lesion sites are greatly different from the classic cases of cortical aphasia. Additional cases of subcortical C/P aphasia may emerge that share some, but not all, of the language features presented in this study, or different combinations of these features as observed in case 9. Damasio and colleagues also report on these features (see p 15) in this issue.⁴⁰ Critical differences in lesion extension of only a few millimeters in one or more directions (particularly more posterior across the temporal isthmus or more anterior to fibers that lead to the genu of the corpus callosum) are responsible for striking differences in language. These small differences in lesion extension demand close inspection of the CT scan, and the differences are not trivial.

Our records indicate that approximately 10% of the aphasia cases on file during the past two-year period had subcortical lesions in the C/P area. Identification of specific syndromes among these patients may lead to specific treatments. For example, one typical case of C/P aphasia with anterior-superior lesion extension showed improvement in speech output and reduced dysarthria with melodic intonation therapy.^{24,25,41} Accurate diagnosis of the aphasia, confident prediction of the prognosis, and development of rational treatment plans all depend on precise clinicoanatomic correlations.

This study was supported in part by the Medical Research Service of the Veterans Administration and in part by grants NS06209 and NS07615 from the Public Health Service.

The following persons cooperated in this study: Leslie M. Zatz, MD, Robert Hayward, MD, Terry L. Jernigan, PhD, Diane Hauck, and Redmond Burke (Radiology Service, Palo Alto VA Medical Center); Alan Robbins, MD, Joanne Andrews, Elizabeth Barrett, Joan Ahern, and Elizabeth Eblan (Radiology Service, Boston VA Medical Center); Donald Willfong and Edward Morgan (Ohio Nuclear Corp, Solon, Ohio); Barbara Barresi, MA, and Michael Walsh, MA (Speech Pathology Service, Boston VA Medical Center); Martha Martin, MA, and John Watson, PhD (Speech Pathology Service, Palo Alto VA Medical Center). Records were made available by D. Frank Benson, MD, Ronald Angel, MD, and James Bird, MD. Jean M. Pieniadz, Ronald Pellowe, and Anne Foundas assisted with the research. Artwork was provided by Charles Foltz, and additional graphics assistance was provided by the Medical Media Service, Palo Alto (Curt Campbell and Esther Fourman) and Boston VA Medical Centers. Ada Jacobs and Claire Sybertz typed the manuscript. The findings were discussed with Harold Goodglass, PhD, Elliot Ross, MD, Antonio Damasio, MD, and Hanna Damasio, MD, who provided many valuable suggestions. Syntex Corp, Sunnyvale, Calif, provided early support for this research.

References

1. Marie P, cited by Hecaen H, Albert ML: *Human Neuropsychology*. New York, John Wiley & Sons Inc, 1978.
2. Penfield W, Roberts L: *Speech and Brain-Mechanisms*. Princeton, NJ, University Press, 1959.
3. Fisher CM: The pathologic and clinical aspects of thalamic hemorrhage. *Trans Am Neurol Assoc* 1959;84:56-59.
4. Ciemins VA: Localized thalamic hemorrhage: A cause of aphasia. *Neurology* 1970;20:776-782.
5. Mohr JP, Watters WC, Duncan GW: Thalamic hemorrhage and aphasia. *Brain Lang* 1975;2:3-17.
6. Mohr JP, Sidman M: Aphasia: Behavioral aspects, in Ariteti S (ed): *American Handbook of Psychiatry*, ed 4. New York, Basic Books Inc, 1975.
7. Luria AR: On quasi-aphasic speech disturbances in lesions of the deep structures of the brain. *Brain Lang* 1977;4:432-459.
8. Walshe TM, Davis KR, Fisher CM: Thalamic hemorrhage: A computed tomographic-clinical correlation. *Neurology* 1977;27:217-222.
9. Hier DB, Davis KR, Richardson EP, et al: Hypertensive putaminal hemorrhage. *Ann Neurol* 1977;1:152-159.
10. Cappa SF, Vignolo LA: 'Transcortical' features of aphasia following left thalamic hemorrhage. *Cortex* 1979;15:121-130.
11. Benson DF: *Aphasia, Alexia and Agraphia*. New York, Churchill Livingstone, 1979, pp 93-100.
12. Alexander M, LoVerme S: Aphasia after left intracerebral hemorrhage. *Neurology* 1980;30:1193-1202.
13. Goodglass H, Kaplan E: *The Assessment of Aphasia*. Philadelphia, Lea & Febiger, 1972.
14. Naeser MA, Hayward RW: Correlation between CT scan findings and the Boston diagnostic aphasia exam. *Neurology* 1978;28:545-551.
15. Hanaway J, Scott WR, Strother CM: *Atlas of the Human Brain and the Orbit for Computed Tomography*. St Louis, Warren H Green Inc, 1977.
16. DeArmond SJ, Fusco MN, Dewey MM: *Structure of the Human Brain*. New York, Oxford University Press, 1976.
17. Matsui T, Hirano A: *An Atlas of the Human Brain for Computerized Tomography*. Tokyo, Igaku-Shoin, 1978.
18. Jernigan TL, Zatz LM, Naeser MA: Semi-automated methods for quantitating CSF volume on cranial computed tomography. *Radiology* 1979;132:463-466.
19. Ross ED: Localization of the pyramidal tract in the internal capsule by whole brain dissection. *Neurology* 1980;30:59-64.
20. Nielsen JM: *Agnosia, Apraxia, Aphasia: Their Value in Cerebral Localization*. New York, Hafner Publishing Co Inc, 1946, pp 119-120.
21. Fisher CM: Capsular infarct: The underlying vascular lesions. *Arch Neurol* 1979;36:65-73.
22. Goodglass H, Klein B, Carey PW, et al: Specific semantic word categories in aphasia. *Cortex* 1966;2:74-89.
23. Zurif EB, Blumstein SE: Language and the brain, in Halle M, Bresnan J, Miller GA (eds): *Linguistic Theory and Psychological Reality*. Cambridge, Mass, Massachusetts Institute of Technology Press, pp 229-245.
24. Albert M, Sparks R, Helm N: Melodic intonation therapy for aphasia. *Arch Neurol* 1973;29:130-131.
25. Sparks RW, Helm NA, Albert ML: Aphasia rehabilitation resulting from melodic intonation therapy. *Cortex* 1974;10:303-316.
26. Spreen O, Benton A: *Neurosensory Center Comprehensive Examination for Aphasia*. Victoria, Canada, University of Victoria, 1969.
27. Kertesz A, Harlock W, Coates R: Computer tomographic localization, lesion size and prognosis in aphasia and non-verbal impairment. *Brain Lang* 1979;8:34-50.
28. Naeser MA, Hayward RW, Laughlin SA, et al: Quantitative CT scan studies in aphasia: I. Infarct size and CT numbers. *Brain Lang* 1981;12:140-164.
29. Bonhoeffer K: Klinischer und Anatomischer Befund zur Lehre von der Apraxie und der 'motorischen Sprachbahn.' *Monatschr Psychiatrie Neurol* 1914;35:113-128.
30. Geschwind N: Disconnexion syndromes in animals and man: II. *Brain* 1965;88:585-644.
31. Mazzeo F, Vignolo AL: Localization of lesions in aphasia: Clinical CT scan correlations in stroke patients. *Cortex* 1979;15:627-654.
32. Damasio H, Damasio A: 'Paradoxical' ear extinction in dichotic listening: Possible anatomic significance. *Neurology* 1979;29:644-653.
33. Rubens A, Johnson MG, Speaks C: Location of lesions responsible for the 'paradoxical ipsilateral ear effect' with dichotic listening tests in patients with aphasia due to stroke. *Neurology* 1978;28:396.
34. Naeser MA, Hayward RW, Laughlin SA, et al: Quantitative CT scan studies in aphasia: II. Comparison of the right and left hemispheres. *Brain Lang* 1981;12:165-189.
35. Romanul FCA: Examination of the brain and spinal cord, in Tedeschi GG (ed): *Neuropathology*. Boston, Little Brown & Co, 1970, pp 131-214.
36. Torvik A, Jorgensen J: Thrombotic and embolic occlusions of the carotid arteries in an autopsy series: II. Cerebral lesion and clinical course. *J Neurol Sci* 1966;3:410-432.
37. Ojemann GA: Subcortical language mechanisms, in Whitaker H, Whitaker HA (eds): *Studies in Neurolinguistics*. New York, Academic Press Inc, 1976, vol 1, pp 103-138.
38. Graybiel AM, Ragsdale CW Jr: Fiber connections of the basal ganglia. *Prog Brain Res* 1979;51:239-283.
39. Goldman PS, Rosvold HE: The effects of selective caudate lesions in infant and juvenile rhesus monkeys. *Brain Res* 1972;43:53-66.
40. Damasio AR, Damasio H: Aphasia with lesions of the basal ganglia and internal capsule. Read at the Research Group of Aphasia Meetings, World Federation of Neurology, Boston, Oct 1, 1980.
41. Helm NA, Naeser MA, Kleeefeld J: CT scan localization and response to melodic intonation therapy. Read before the Academy of Aphasia Meeting, Bass River, Mass, Oct 7, 1980.