

Neuroimaging and Language Recovery in Stroke

Margaret A. Naeser and Carole L. Palumbo

*Department of Neurology and Boston University Aphasia Research Center, Boston University School of Medicine
and Boston Department of Veterans Affairs Medical Center, Boston, Massachusetts, U.S.A.*

Summary: This article reviews the use of a chronic computed tomography (CT) scan (performed after 2 or 3 months following stroke onset) in assessing a patient's potential for recovery of speech and comprehension in the long term (after 6-12 months following stroke onset). Not all aphasia patients recover the ability to produce meaningful speech after a stroke. This article discusses the neuroanatomical areas to be examined on CT scan, in order to predict which stroke patients are not likely to recover meaningful speech, even for as long as 10 years following stroke onset. These neuroanatomical areas are located in deep, subcortical white matter areas; they are not in the cortex. It is important to have information regarding potential for long-term recovery of speech, so that appropriate non-verbal treatment programs can be initiated. A non-verbal computer-assisted treatment program is presented, in which severely affected patients are taught to communicate using pictures and icons on a computer screen. **Key Words:** Computed tomography—Aphasia—Speech disorders—Language recovery.

This article summarizes our method of computed tomography (CT) scan analysis, which may help predict a stroke patient's potential for long-term language recovery. Three areas of language recovery are presented: (a) recovery of auditory language comprehension (6 months or 1 year poststroke); (b) recovery of spontaneous speech (including which patients are likely to have partial recovery of speech after 6 months or 1 year, versus which patients are likely to have no meaningful speech even 9-10 years poststroke); and (c) potential of patients with no speech to communicate via computer-assisted nonverbal treatment; the computer-assisted visual communication (C-ViC) program trains the nonverbal patient to use pictures and icons on a Macintosh computer screen to communicate needs and ideas.

The CT scans on which the predictions for long-term recovery are based are performed at *least* 2 or 3 months post-stroke onset (MPO). The borders of the lesion are better visualized on the CT scans per-

formed 2 or 3 MPO than on acute CT scans performed earlier (Palumbo and Naeser, in preparation). [Special issues and problems observed with current magnetic resonance imaging (MRI) technology are discussed at the end of the article.]

The term "recovery" refers to long-term language behavior, i.e., the late language scores obtained by a patient 6 MPO or even 1 or more years poststroke. The term "recovery" does not refer to "amount of change" or "rate of change" from early time 1 scores (at 1 or 2 MPO) to late time 2 scores (at 6 months or 1 or more years postonset).

Lesion size analysis is not included in most of the material presented in this article, because research from our laboratory and others has not found total lesion size to be helpful in making predictions for recovery, except in very large or very small lesions (Kertesz et al., 1979; Vignolo, 1979; Selnes et al., 1983, 1984; Naeser, et al., 1987, 1989). For example, the mean lesion size for severe global aphasia patients with cortical and subcortical lesions is 28.1% left-hemisphere tissue damage (SD, 11.2), as in complete left-middle cerebral-artery-territory ischemic infarction. The mean lesion size for global aphasia patients with a primarily subcortical lesion

Address correspondence and reprint requests to Dr. M. Naeser at Department of Veterans Affairs Medical Center (116-B), 150 So. Huntington Avenue, Boston, MA 02130, U.S.A.

is only 13.6% left-hemisphere tissue damage (SD, 3.2) (Naeser, 1983). Subcortical global aphasia patients have a total lesion size (13.6%) less than half of that observed in global aphasia patients with cortical and subcortical lesions (28.1%), yet these lesions produce similar behavioral deficits. Subcortical global aphasia patients have lesions primarily in the putamen and internal capsule area, with white matter lesion extension in three directions: anterior (across the anterior limb, internal capsule, and white matter near the frontal horn, deep to Broca's area); posterior (across white matter in the temporal isthmus, deep to Wernicke's area); and superior, into the white matter near the body of the lateral ventricle (Naeser et al., 1982). These subcortical global aphasia patients have lesions that undercut the critical white matter pathways for speech and comprehension. The small subcortical white matter lesions may extend only a few millimeters in one direction or another and yet produce profound language deficits. Hence, over the last decade, our research has increasingly shifted away from overall lesion size analysis to precise CT site analysis.

METHOD OF LESION SITE ANALYSIS ON CT SCANS

Most CT scans are obtained approximately 15–20° to the canthomeatal line, with 10-mm slice thickness and 7-mm intervals through the ventricles, beginning at the level of the suprasellar cistern (Fig. 1A). Our method of lesion site analysis includes examination of the lesion in specific, separate cortical language areas as well as examination of the lesion in specific, separate subcortical areas. These separate neuroanatomical areas are diagrammed on the CT scan slices shown in Fig. 1B. Most of these neuroanatomical areas are listed in CT scan atlases (DeArmond et al., 1976; Hanaway et al., 1977; Matsui and Hirano, 1978).

The extent of lesion (degree of infarction) within each separate neuroanatomical area in Fig. 1B is visually assessed using a 0–5-point rating scale: 0 = no lesion; 1 = equivocal lesion; 2 = small, patchy, or partial lesion; 2.5 = patchy—less than half of the area has a lesion; 3 = half of the area has a lesion; 3.5 = patchy—more than half of the area has a lesion; 4 = more than half of the area has a solid lesion; and 5 = total area has solid lesion. An extent-of-lesion rating is recorded for each separate cortical and subcortical area on the CT scan slices shown in Fig. 1B.

An extent-of-lesion rating >3 (indicating a lesion in greater than half of a specific area) for a specific

neuroanatomical site is of special importance, since >3 has been observed to correlate with increased severity of language deficit, reduced potential for recovery of auditory comprehension (Naeser et al., 1987, 1990), and reduced potential for recovery of spontaneous speech (Naeser et al., 1989). All scans are rated by at least two experienced raters and conferenced data are used; in previous studies, we have observed an interrater reliability coefficient of 0.93 (Borod et al., 1984).

LESION SITE ANALYSIS AND RECOVERY OF AUDITORY LANGUAGE COMPREHENSION

Wernicke's Aphasia

This section explains how to analyze CT-scan lesion sites to predict potential for long-term recovery of auditory comprehension in Wernicke's aphasia. Wernicke's aphasia patients produce rapid, well-articulated, "fluent" paraphasic speech, but they have poor auditory language comprehension (Goodglass and Kaplan, 1972).

Ten male Wernicke's aphasia patients were studied who were classified at least 6 MPO as mild good-recovery cases ($n = 5$) or moderate-severe poor-recovery cases ($n = 5$) (Naeser et al., 1987). Each patient was right-handed and had suffered a single-episode left-hemisphere occlusive-vascular stroke between the ages of 47 and 71 years (mean, 58.4; SD, 6.9); there were no significant group differences. The CT scans used for lesion site analysis were performed 3–36 MPO.

Auditory comprehension test scores from the Boston Diagnostic Aphasia Exam (BDAE) (Goodglass and Kaplan, 1972) were examined from two time periods. Time 1 (T1) scores were obtained 1–2 MPO and time 2 (T2) scores were obtained at least 6 MPO. The test to determine T2 scores was administered 6–13 MPO for the mild group and 12–38 MPO for the moderate-severe group. The T2 scores for the moderate-severe group were determined as long after onset as possible to maximize the potential recovery period.

Patients were separated on the basis of T2 scores as follows: (a) good-recovery cases scored >0 (above the 50th percentile) on the BDAE overall auditory comprehension Z score, and (b) poor-recovery cases scored <0 (below the 50th percentile; Fig. 2). The reader is referred to the original paper for exact T1 and T2 test scores for all 10 Wernicke's aphasia patients (Naeser et al., 1987).

The CT scans were analyzed with two methods: (a) lesion site analysis, already described, where the

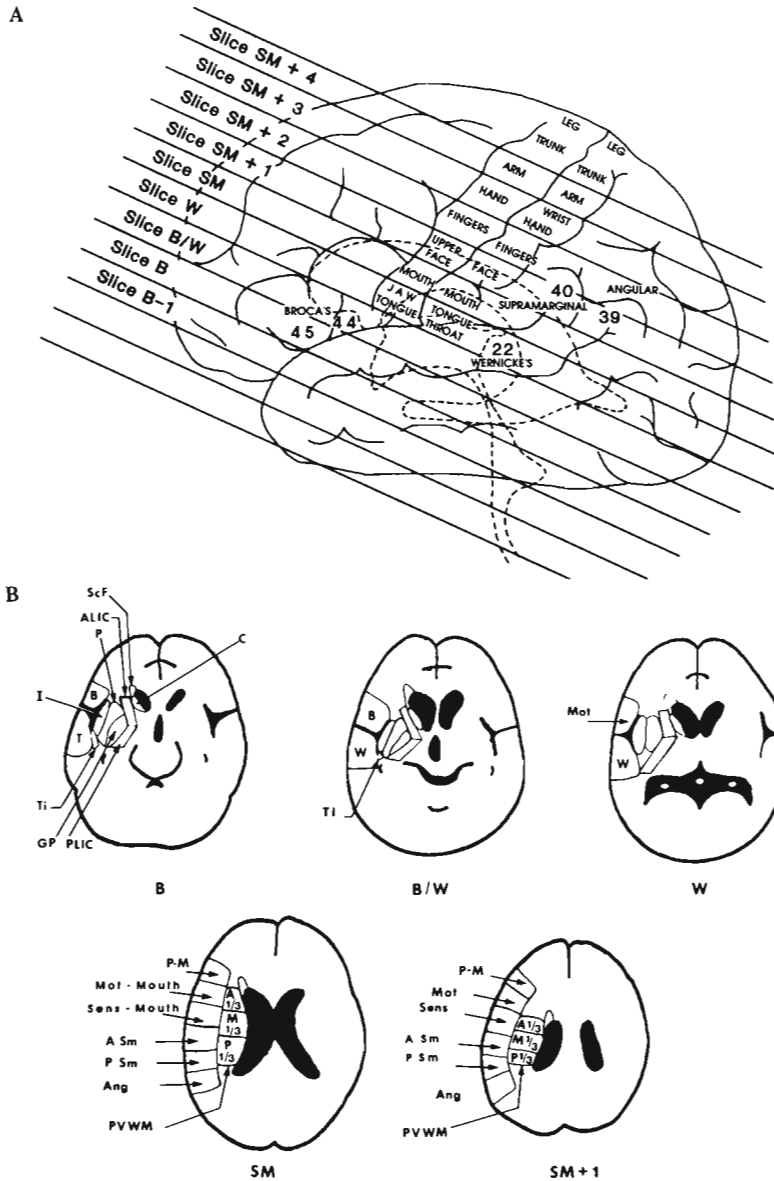


FIG. 1. A: Lateral diagram of the location of cortical language areas in relationship to the ventricular system (dotted lines). The CT scan slices are marked at 20° to the canthomeatal line, similar to the angle at which they are performed. Numbers refer to Brodmann's areas as follows: 44 and 45, Broca's area; 22, Wernicke's area; 40, supramarginal gyrus area; 39, angular gyrus area. The different parts of the motor and sensory homunculi are labeled for each CT scan slice. Note that the motor-sensory cortex areas for the mouth are located on CT scan slice SM. B: Location of specific neuroanatomical areas that are visually assessed for extent-of-lesion ratings on CT scans. The CT scan slices B, B/W, W, SM, and SM + 1 are labeled according to the Naeser and Hayward (1978) slice-labeling system. Each neuroanatomical area is examined using a 0-5-point scale (0, no lesion; 3, half of area has lesion; 5, entire area has solid lesion; see text). Other abbreviations: B, Broca's area (45 on slice B; 44 on slice B/W); T, temporal lobe anterior-inferior to Wernicke's area on slice B; Ti, temporal isthmus; I, insular structures, including insula, extreme capsule, claustrum, and external capsule; P, putamen; GP, globus pallidus; ALIC, anterior-limb internal capsule; PLIC, posterior-limb internal capsule; ScF, medial subcallosal fasciculus; C, caudate; W, Wernicke's area (22); Mot, motor cortex; P-M, premotor cortex; Sens, sensory cortex; A Sm, anterior supramarginal gyrus; P Sm, posterior supramarginal gyrus; Ang, angular gyrus; PVWM, periventricular white matter area (A $\frac{1}{3}$, anterior one third of PVWM; M $\frac{1}{3}$, middle one third of PVWM; P $\frac{1}{3}$, posterior one third of PVWM). (Reprinted from Naeser et al., 1989.)

0-5-point extent-of-lesion rating scale was used visually to rate the amount of infarction (degree of damage) within each specific cortical and subcortical area, and (b) total lesion size analysis where the total percentage of left-hemisphere temporoparietal damage was quantified using a computer-based technique (Jernigan et al., 1979; Naeser et al., 1981).

Since the time of Wernicke, there have been multiple interpretations regarding the exact location and limits of "Wernicke's area" (Bogen and Bogen, 1976). For the purpose of this study, Wernicke's area was defined as the posterior two thirds of the left superior temporal gyrus area. On CT scans, the

anterior half of Wernicke's area (i.e., the middle third of the superior temporal gyrus area) was located lateral to the maximum width of the third ventricle on slice B/W (Fig. 1B). In addition, the posterior half of Wernicke's area (i.e., the posterior third of the superior temporal gyrus area) was located lateral to the roof of the third ventricle on slice W (Fig. 1B). The supramarginal and angular gyrus areas in the parietal lobe were analyzed on slices SM and SM + 1 (Fig. 1B).

All good-recovery Wernicke's patients with T2 auditory comprehension Z scores >0 had lesions in half or less of Wernicke's area. All poor-recovery Wernicke's patients with T2 auditory comprehen-

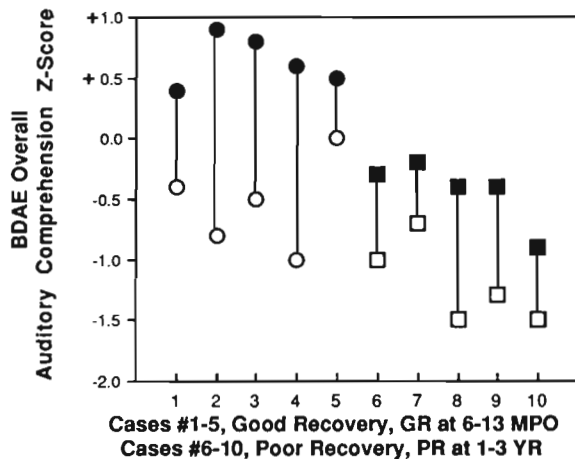


FIG. 2. Time 1 (1–2 MPO) and time 2 (6 MPO or 1–3 years) overall auditory comprehension Z scores for 10 Wernicke’s aphasia patients. There was overlap in the T1 scores among some of the good-recovery (GR) and poor-recovery (PR) patients; thus, the T1 test scores could not be used on a case-by-case basis to predict GR or PR 6 MPO. (○), T1, GR; (●), T2, GR; (□), T1, PR; (■), T2, PR.

sion Z scores <0 had lesions in more than half of Wernicke’s area (Fig. 3A). The correlation between T2 BDAE overall auditory comprehension Z scores and extent of lesion within Wernicke’s area was -0.91 ($p < 0.001$).

The total left temporoparietal lesion size (as a percentage of total area) was not useful in distin-

guishing between cases with good recovery and those with poor recovery of auditory comprehension at T2 (Fig. 3B). The correlation between the T2 auditory comprehension Z scores and the total percent left temporoparietal lesion size was -0.56 (NS). There was also no significant correlation between amount of change from T1 to T2 and extent-of-lesion rating within Wernicke’s area ($r = -0.494$; NS), nor was there a significant correlation between amount of change and total percent left-hemisphere temporoparietal lesion size ($r = -0.013$; NS).

There was a significant correlation, however, between the lesion size and the T2 visual confrontation naming scores from the BDAE (-0.88 ; $p < 0.001$). This finding is in general agreement with Kertesz (1979), who found that the highest degree of correlation between total lesion size and severity of aphasia existed for anomic aphasia patients.

Case Examples

Figure 4 shows the CT scan of a Wernicke’s aphasia patient with a lesion in Wernicke’s cortical area only on slice W and good recovery of auditory comprehension at 7–10 MPO; the lesion was in about half of Wernicke’s total area. Figure 5 shows the CT scan of a Wernicke’s aphasia patient with a lesion in Wernicke’s cortical area on both slice B/W

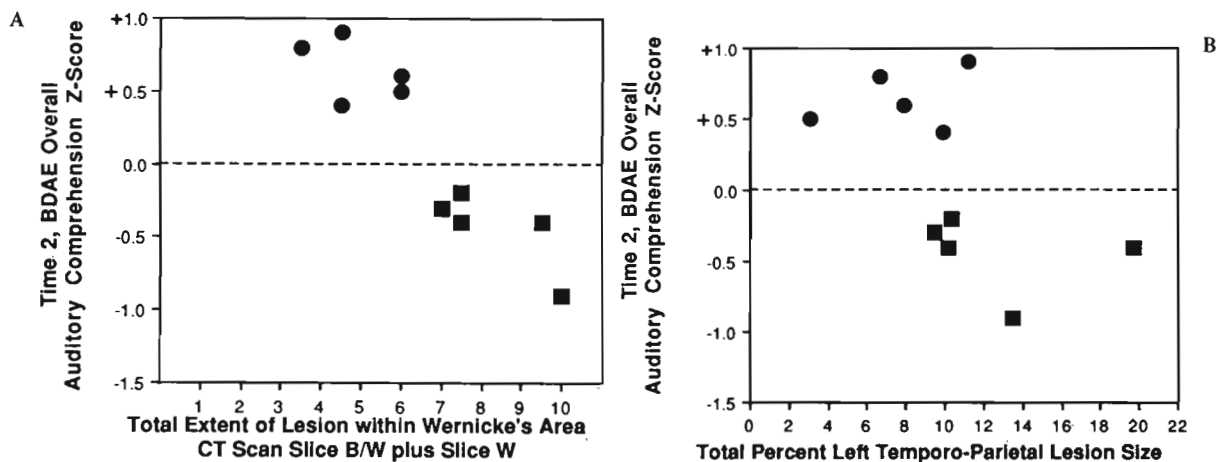


FIG. 3. A: This graph shows a highly significant correlation ($r = -0.91$; $p < 0.001$) between the total extent-of-lesion ratings within Wernicke’s area on CT scan slices B/W and W and T2 BDAE overall auditory comprehension Z scores for 10 Wernicke’s aphasia patients. A total extent-of-lesion rating of 10 reflects a rating of 5 (complete solid lesion) in Wernicke’s area on each of CT slices B/W and W. Patients with total extent-of-lesion ratings ≤ 6 have lesion in half or less of Wernicke’s area; these patients had good recovery 6 MPO, with T2 BDAE Z Scores >0 or >50 th percentile. Patients with total extent-of-lesion ratings >6 have lesions in more than half of Wernicke’s area; these patients still had poor recovery 1–3 years post-stroke onset. (●), GR, T2 BDAE Z-Sc; (■), PR, T2 BDAE Z-Sc. B: This graph shows no significant correlation ($r = -0.56$) between total percent left temporoparietal lesion size on CT scan slices B, B/W, W, SM, and SM + 1 and T2 BDAE overall auditory comprehension Z scores for 10 Wernicke’s aphasia patients. There was overlap between the GR cases and the PR cases around the 10% lesion size value. Total lesion size could not be used to separate GR from PR at T2 testing. Only total extent-of-lesion ratings within Wernicke’s area could separate GR from PR cases at T2 testing. (●), GR, T2 BDAE Z-Sc; (■), PR, T2 BDAE Z-Sc.

and slice W and poor recovery of auditory comprehension at 14 MPO; the lesion was in all of Wernicke's area.

Our results support the notion that extent-of-lesion ratings for Wernicke's area on a CT scan performed 2 or 3 MPO may be useful in predicting long-term recovery of auditory comprehension in Wernicke's aphasia patients. Those patients with lesion in half or less of Wernicke's area have a better prognosis for recovery of auditory comprehension within the first year poststroke.

Global Aphasia

This section explains how to analyze CT scan lesion sites to predict potential for long-term recovery of auditory comprehension in severe global aphasia. Global aphasia patients have severe deficits in speech output and comprehension, as well as in repetition, naming, reading, and writing.

Fourteen right-handed stroke patients with global aphasia (12 men and 2 women; ages, 50–66 years) who had unilateral left-hemisphere ischemic infarcts were studied (Naeser et al., 1990). All patients had been tested a minimum of twice with the BDAE (Goodglass and Kaplan, 1972). T1 testing was done 1–4 MPO. T2 testing was done 1–2 years poststroke. All patients had been classified as globally aphasic at T1 on the basis of the BDAE, and all patients had BDAE auditory comprehension Z scores at T1 that were below -1.0 , showing severe auditory comprehension deficits.

All patients had CT scans obtained 2 MPO (2–110 MPO). CT scan lesion site analysis was performed. Extent-of-lesion ratings were computed for the separate cortical and subcortical areas shown in Fig. 1B, including major frontal, parietal, and temporal lobe areas, as well as subcortical structures. Special emphasis was placed on analyzing the extent of lesion in Wernicke's cortical area and immediate subjacent white matter on slices B/W and W and on the extent of lesion in the subcortical temporal lobe structure and the subcortical temporal isthmus area on slices B and B/W, respectively. See Fig. 1B for location of these areas.

The subcortical temporal isthmus area contains auditory pathways from the medial geniculate body to Heschl's gyrus. Lesion in the temporal isthmus area has been associated since the time of Nielsen (1946) with producing auditory language comprehension deficits. In the present study, the temporal isthmus was defined as the white matter inferior to the sylvian fissure/insular area and anterior to the temporal horn on slices B and B/W (Nielsen, 1946; Naeser et al., 1982); see Fig. 6.

Nielsen has described the small subcortical temporal isthmus area as follows: "It measures from 10 to 15 mm across and is in height nearly equal to that of the thalamus. . . . The artery of supply of the isthmus is the anterior choroidal." In the present study, only the anterior half of the temporal isthmus was evaluated for extent of lesion in auditory pathways; the posterior half of the temporal isthmus

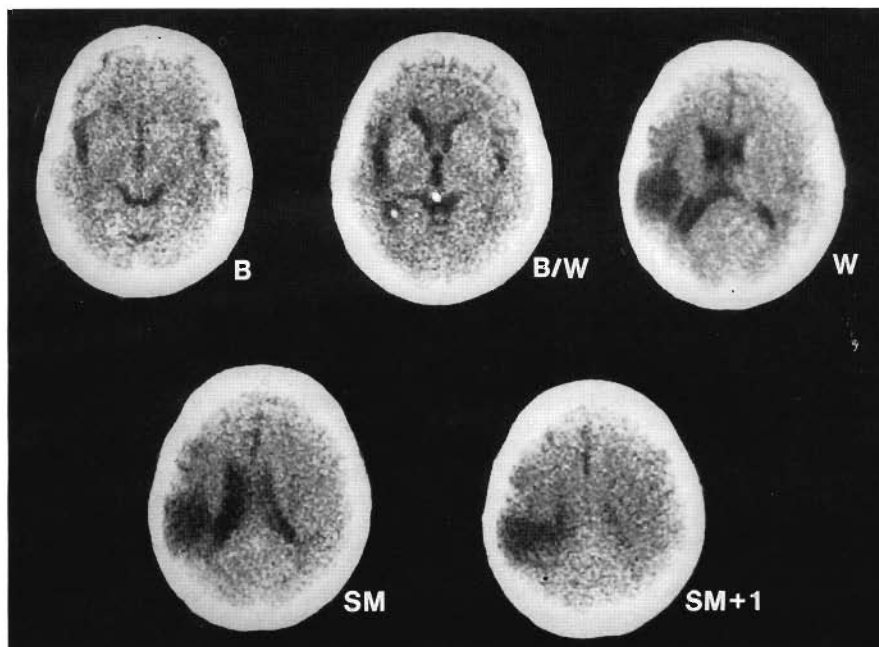
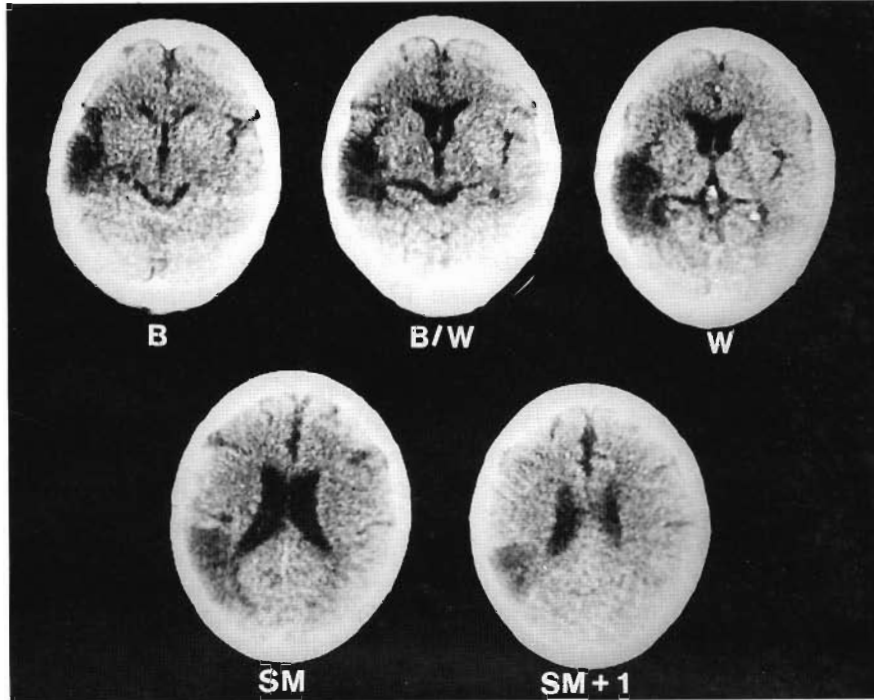


FIG. 4. CT scan performed 24 MPO in a patient with mild Wernicke's aphasia who had good recovery (0.9 BDAE auditory comprehension Z score) at T2 testing (7 MPO). Lesion was present only in the posterior half of Wernicke's area on slice W (extent-of-lesion rating, 4.5). There was an additional parietal lobe lesion in the anterior and posterior supramarginal gyrus areas, surface and deep. (Reprinted from Naeser et al., 1987.)

FIG. 5. CT scan performed 7 MPO in a patient with severe Wernicke's aphasia who had poor recovery (-0.9 BDAE auditory comprehension Z score) at T2 testing (14 MPO). Extensive lesion was present in Wernicke's area on both slices B/W and W (extent-of-lesion rating, 5 on each slice; total extent-of-lesion rating, 10). A large temporal lobe lesion was also present on slice B (extent-of-lesion rating, 4.5), anterior and inferior to Wernicke's area. There was an additional parietal lobe lesion in the anterior and posterior supramarginal gyrus areas, surface and deep and some lesion in the angular gyrus on slices SM and SM + 1. (Reprinted from Naeser et al., 1987.)



contains visual pathways. The anterior half of the temporal isthmus area is only ~1 mm in size on a CT scan.

On the basis of lesion site analysis, the subjects were classified into two groups. Group 1 global aphasia cases had cortical-subcortical lesions in the frontal, parietal, and temporal (FPT) lobes, including Wernicke's cortical area. Each case in group 1 (n = 9) had a lesion in at least half of Wernicke's cortical area. Group 1 cases are labeled *FPT cases*

in this article. Group 2 global aphasia cases (n = 5) also had cortical-subcortical lesions in the frontal and parietal (FP) lobes but only subcortical lesions in the temporal lobe including the subcortical temporal isthmus area (Ti); group 2 cases are labeled *FPTi cases* in this article. Both groups had similar mean extent-of-lesion ratings in frontal and parietal and subcortical areas, including the subcortical Ti area. All cases in the FPT group had lesions in more than half of Wernicke's cortical area; none of the

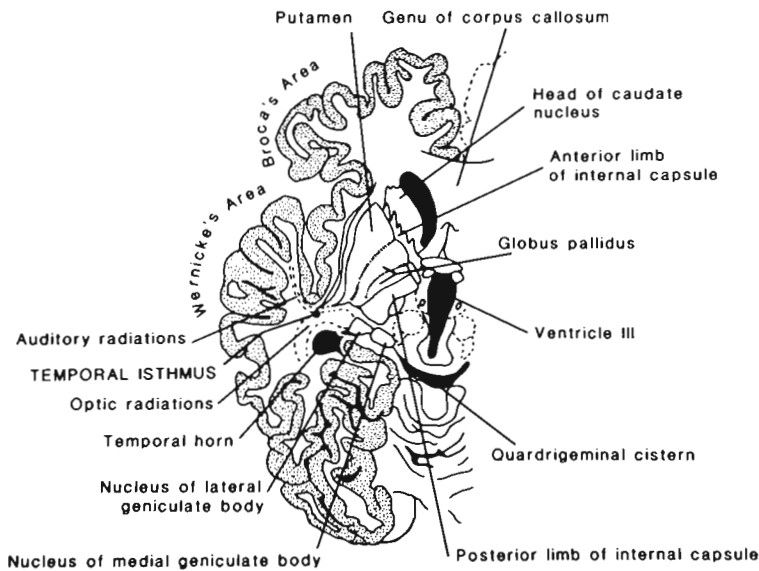


FIG. 6. Schematic drawing of CT scan slice B/W (left hemisphere) showing location of the auditory radiations within the anterior half of the subcortical temporal isthmus area (Ti). The Ti is located in the white matter inferior to the sylvian fissure and superior to the temporal horn. (Reprinted from Naeser et al., 1990.)

cases in the FPTi group had a cortical lesion in Wernicke's area.

There was no significant difference in age at stroke onset between the two groups: FPT group: mean, 58.2 years; SD, 4.2; FPTi group: mean, 57.8 years; SD, 5.0. Each group had one woman. There were no significant differences between the two groups in terms of how long after stroke onset when T1 or T2 testing was performed.

In four of the five FPTi cases, the T2 auditory comprehension Z scores were above -0.5 ; in eight of the nine FPT cases, they were below -0.5 (Fig. 7). There was a significantly greater increase ($p < 0.01$) in the amount of recovery that had taken place from T1 to T2 in the FPTi group than in the FPT group in the BDAE overall auditory comprehension Z score. The mean change from T1 to T2 for the FPTi group was 1.58, while for the FPT group it was only 0.65.

The FPTi cases had a significantly greater ($p < 0.01$) amount of recovery from T1 to T2 at the single-word level of comprehension (word-discrimination and body-part-identification subtests) than did the FPT cases. Patients in the FPTi group had significantly higher ($p < 0.01$) body-part-identification absolute scores at T2 than did FPT patients (T2 FPTi mean, 14.3; SD, 3.6; T2 FPT mean, 5.7; SD, 4.5).

Thus, most global aphasia cases with temporal lobe lesions that included at least half of Wernicke's cortical area had poor recovery of auditory compre-

hension 1–2 years poststroke. Most global aphasia cases with only subcortical temporal lobe lesions including the subcortical temporal isthmus area had better recovery of auditory comprehension 1–2 years poststroke.

There were no significant differences between the two groups in the amount of recovery that had taken place from T1 to T2 in the number of words per phrase in spontaneous speech, single-word repetition, or naming. Most subjects in each group remained severely impaired in these areas at T2. The reader is referred to the original paper for exact T1 and T2 scores (Naeser et al., 1990).

Case Examples

Figure 8 shows the CT scan and BDAE auditory comprehension Z scores for an FPTi case with relatively good recovery of auditory comprehension 1 year postonset. Figure 9 shows the CT scan and BDAE auditory comprehension Z scores for an FPT case with poor recovery of auditory comprehension 8 years poststroke.

Results from this study suggest that CT scan lesion site analysis in global aphasia patients can help predict which subset of these severely affected patients has greater potential for recovery of some auditory language comprehension (especially single-word comprehension) 1 or 2 years postonset. A majority of the patients (~80%) with only a subcortical temporal isthmus lesion in the temporal lobe (versus a cortical lesion in Wernicke's area in the temporal lobe) had increased recovery of single-word comprehension 1 year postonset.

Our findings support the notion of Sarno and Levita (1979, 1981) that global aphasia patients are not a homogeneous group. The results suggest that careful examination of cortical versus subcortical lesions in the temporal lobe can result in information that may help predict a subset of global aphasia patients who have potential for increased recovery of auditory comprehension 1 or 2 years poststroke. Extent-of-lesion ratings should be performed on CT scans obtained 2 or 3 MPO, because the exact borders of an infarct are not well-visualized on CT scans performed earlier.

LESION SITE ANALYSIS AND RECOVERY OF SPONTANEOUS SPEECH

This section explains how to analyze CT scan lesion sites to predict which patients are likely to have partial recovery of speech (nonfluent speech) 6 months or 1 year postonset versus which patients

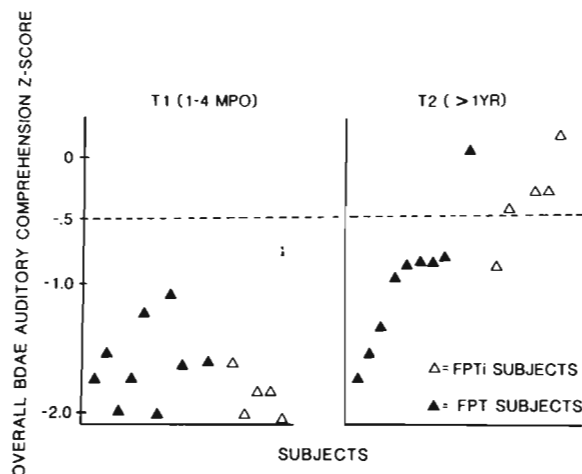


FIG. 7. Graph of BDAE overall auditory comprehension Z scores for all cases at T1 and T2 testing. Note that at T1 testing, not one FPT or FPTi case achieved a Z score better than -1.0 . At T2 testing, four of five FPTi cases achieved Z scores better than -0.5 , but only one of nine FPT cases achieved a Z-score better than -0.5 . (Reprinted from Naeser et al., 1990.)

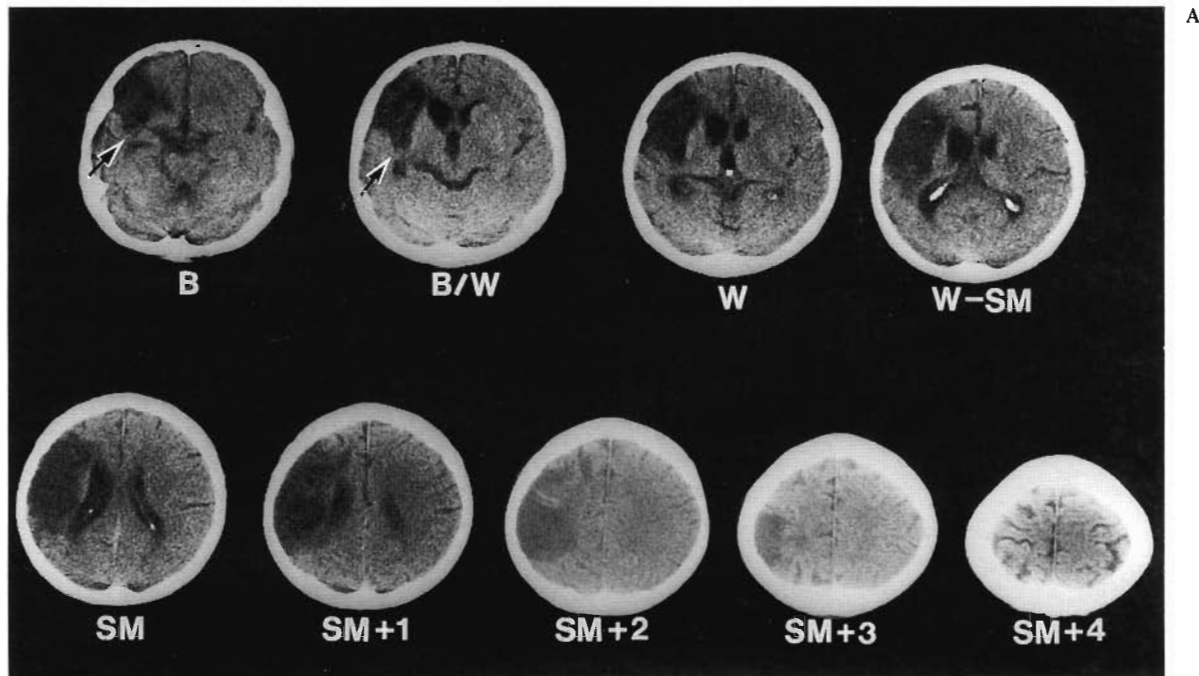
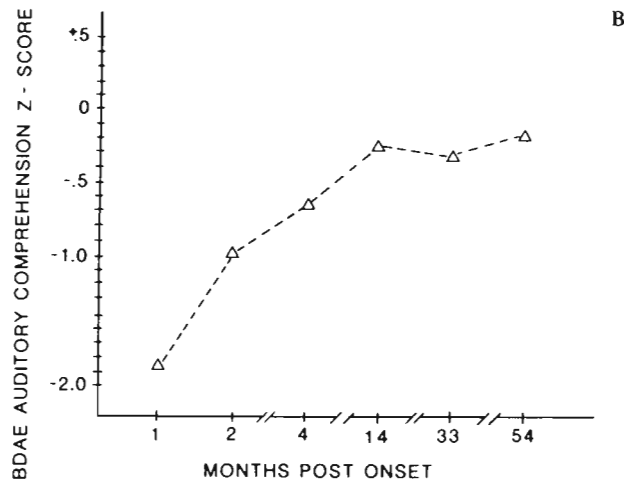


FIG. 8. A: CT scan at 33 MPO of a 61-year-old FPTi patient shows extensive cortical-subcortical lesion in the frontal and parietal lobes but only subcortical temporal lobe lesion in the temporal isthmus area at slices B and B/W (arrows). Note complete sparing of Wernicke's cortical area on slices B/W and W. **B:** Graph shows this patient's BDAE overall auditory comprehension Z scores over a period of several months postonset. Note good recovery of auditory comprehension beginning 2-4 MPO. The patient's BDAE auditory comprehension Z scores were -0.24 , -0.33 , and -0.18 at 14, 33, and 54 MPO, respectively. (Reprinted from Naeser et al., 1990.)



are likely to have no meaningful speech even 9 years postonset. The term "nonfluent" refers to speech that is produced slowly and has poor articulation, short phrase length (one to three words per phrase), and limited grammar.

Research in our laboratory and others has demonstrated that lesions in subcortical white matter areas can profoundly limit recovery of spontaneous speech (Hier et al., 1977; Naeser et al., 1982; Alexander et al., 1987; Naeser et al., 1989). In Naeser et al. (1989), for example, we observed recovery of spontaneous speech to be related to the amount of lesion in two deep, subcortical, white matter areas, combined: the medial subcallosal fasciculus area,

which is located deep to Broca's area; and the middle one third of the periventricular white matter area, which is located deep to the motor-sensory cortex area for the mouth.

The medial subcallosal fasciculus area (medial ScF area), anterolateral to the frontal horn, contains in part projections from the supplementary motor area (SMA) and from cingulate gyrus area 24 to the head of the caudate; it is believed to be involved with initiation of speech (Fig. 1B). The middle one third of the periventricular white matter area ($M\frac{1}{3}$ PVWM), adjacent to the body of the lateral ventricle, contains in part motor-sensory projections for the mouth and is believed to be involved

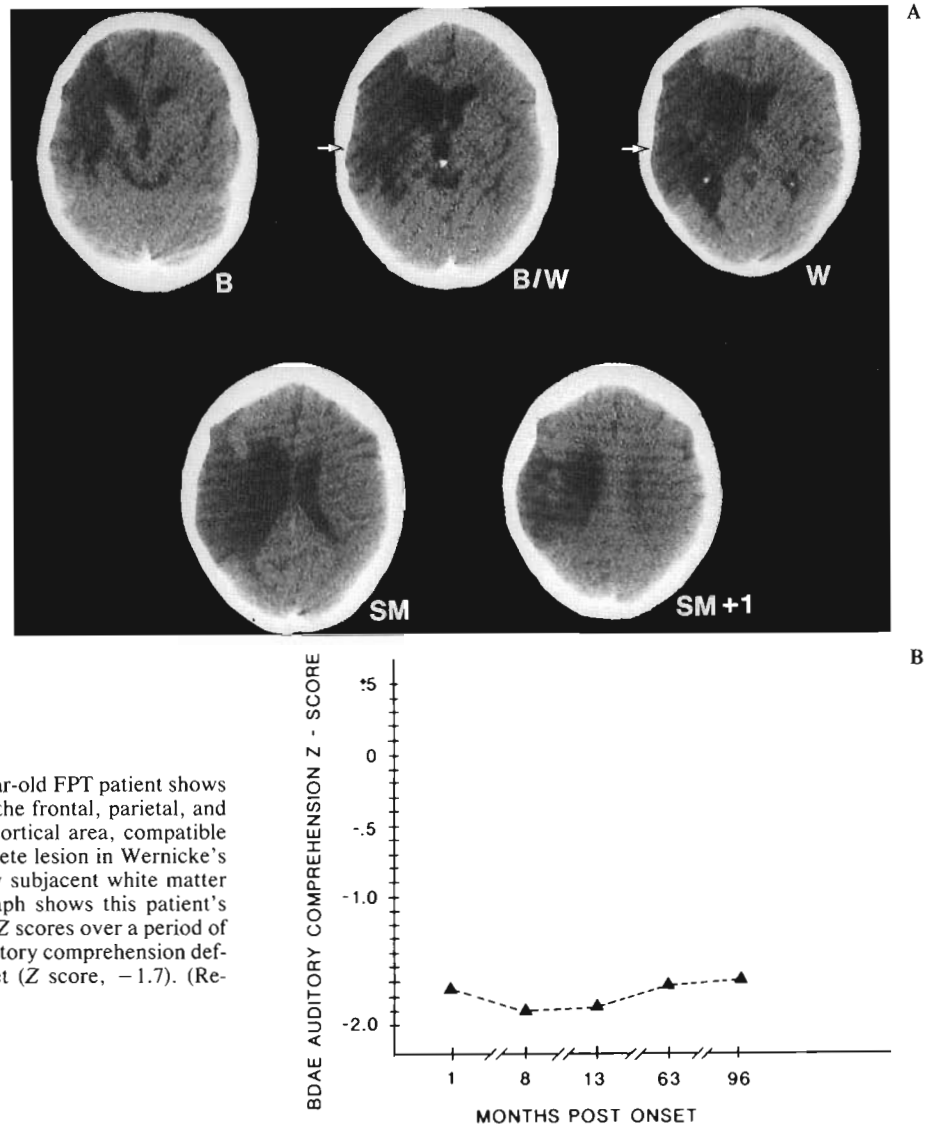


FIG. 9. A: CT scan at 8 MPO of a 61-year-old FPT patient shows extensive cortical-subcortical lesion in the frontal, parietal, and temporal lobes, including Wernicke's cortical area, compatible with global aphasia. There was a complete lesion in Wernicke's cortical area, including the immediately subjacent white matter on slices B/W and W (arrows). B: Graph shows this patient's BDAE overall auditory comprehension Z scores over a period of several months postonset. A severe auditory comprehension deficit was still present 8 years post onset (Z score, -1.7). (Reprinted from Naeser et al., 1990.)

with motor-sensory aspects of speech production (Fig. 1B).

In Naeser et al. (1989), we observed that when extensive lesion was present in *both* of the two subcortical white matter areas, there was no recovery of meaningful speech; the patient showed no ability to produce meaningful spontaneous speech as late as 9 years postonset. Patients with lesions in both areas may have some severely limited speech (limited to "yes," "no," and/or strongly emotional words such as curses), but they have no meaningful propositional speech. (Additional neural connections contained within each of these two subcortical white matter areas are described later in this section).

The methodology and results from our study

(Naeser et al., 1989) on speech recovery (or lack thereof) are summarized as follows: The CT scans and number of words per phrase in spontaneous speech were examined for 27 right-handed aphasia patients (24 men and 3 women) who had had single-episode left-hemisphere occlusive-vascular strokes (thromboembolic infarcts). The mean age at onset was 57.6 years (SD, 7.6; range, 35–69). Each patient had a CT scan performed 2 months to 9 years following stroke onset.

The number of words per phrase for spontaneous speech was determined from elicited spontaneous speech samples for description of the "cookie theft picture" from the BDAE (Goodglass and Kaplan, 1972). These speech samples were obtained from the most recent testing time available, 6 months to

9 years following stroke onset. The speech samples were used to assign patients to four groups based on severity of impairment of spontaneous speech. The classification of patients by deficit in speech production ability was carried out independent of the CT scan lesion site analysis.

Group 1

Group 1 included six men and one woman who were able to produce either no speech or only a few irrelevant words in describing the cookie theft picture. The BDAE auditory comprehension *Z* scores ranged from -1.60 to -0.11 . Scores for naming pictures were 0–19. Some patients in this group were not globally aphasic in all areas of language.

Group 2

Group 2 included 10 men who produced only stereotypies in describing the cookie theft picture. Speech samples included “Boom . . . boom,” “Morning, morning . . . boy, boy,” and “1, 2, 3, 4, 5, . . . boom, boom.” BDAE auditory comprehension *Z* scores ranged from -1.9 to $+0.09$. Scores for naming pictures were 0–24. This group was similar to group 1 in that not all cases were globally aphasic in all areas of language.

Group 3

Group 3 consisted of four men and one woman who produced a few words and/or some overlearned phrases in describing the cookie theft picture. Speech samples included phrases such as “There, too . . . there, too . . . um . . . I don’t know . . . that’s all I guess gee whiz. I don’t know, that’s all . . . well . . . that, too and there and there.” The patients’ spontaneous speech was more difficult to classify and was considered borderline between the most severe cases (i.e., groups 1 and 2) and the least severe cases (group 4) in this study. BDAE auditory comprehension *Z* scores ranged from -2.1 to $+0.29$. Scores for naming pictures were 0–42. This group was similar to groups 1 and 2 in that not all cases were globally aphasic in all areas of language.

Group 4

Group 4 consisted of four men and one woman who produced verbal information relevant to the cookie theft picture with slow, poorly articulated, agrammatic (nonfluent) speech. Speech samples included such phrases as, “The wady is doing her

dishes. Sink undis over uh. . . . The window is open and the w-won . . . a very funny day outside . . . ook children . . . a boy and a girl.” BDAE auditory comprehension *Z* scores ranged from $+0.38$ to $+0.93$. Scores for naming pictures were 58–101. This group had milder deficits than the other three groups in all language modalities.

CT scan lesion site analysis was performed. Extent-of-lesion ratings were recorded for each separate cortical and subcortical area on the CT scan slices shown in Fig. 1B.

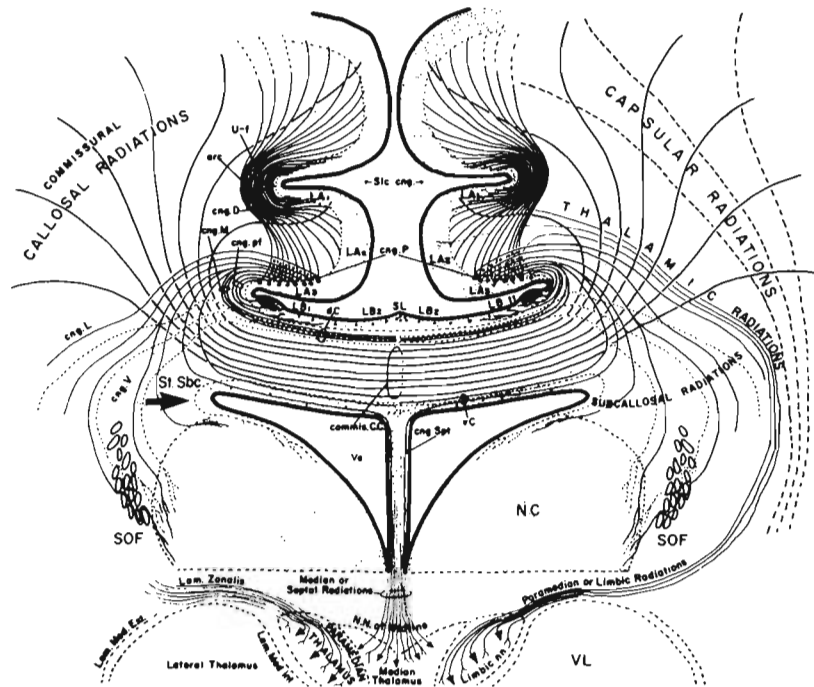
No significant differences (Mann–Whitney *U* tests; $p < 0.01$ and beyond) were observed in the extent-of-lesion ratings for specific lesion site areas between the aphasia patients with no speech (group 1) and those with stereotypies (group 2). Therefore, the lesion site data from these two groups were combined, forming a no speech/stereotypies group ($n = 17$) for comparison with nonfluent Broca’s group 4 ($n = 5$). (The lesion site data for patients who used only a few words and/or some overlearned phrases—group 3—are discussed later.)

When the extent-of-lesion ratings for each neuroanatomical area for all cases were examined, there was no single neuroanatomical area which could alone distinguish the 17 no speech/stereotypies cases from the 5 nonfluent Broca’s cases. However, when the extent-of-lesion ratings were examined for two deep, subcortical, white matter areas *combined*, the total ratings produced no overlap between the no speech/stereotypies cases and the nonfluent Broca’s cases. The two deep, subcortical areas were the medial ScF area (mean lesion extent across slices B and B/W) and the $M\frac{1}{3}$ PVWM area on slice SM. The location of these two areas are marked in the shaded areas on scan slices B, B/W, and SM in Fig. 10A.

A graph showing the total extent-of-lesion ratings for the two deep white matter areas combined for each no speech/stereotypies and nonfluent Broca’s case is provided in Fig. 10B. Each no speech/stereotypies case had a total extent-of-lesion rating >7 , and each nonfluent Broca’s case had a total extent-of-lesion rating <6 . No other lesion site combination could separate these 22 cases into the two groups.

The mean extent-of-lesion ratings in the medial ScF area alone were not adequate to separate these two very different groups of patients; the extent-of-lesion ratings in the $M\frac{1}{3}$ PVWM alone also were not adequate. It was only by the combination of these two lesion site areas that the two groups were suc-

FIG. 11. Drawing in coronal plane from Yakolev and Locke (1961) shows the location of the medial subcallosal fasciculus (stratum subcallosum St Sbc) in the lateral angle of the frontal horn (arrow) in monkey brain. Note that the connections from the cingulate gyrus and supplementary motor area to the head of the caudate are located within the St Sbc area immediately lateral to the frontal horn. (Reprinted from Naeser et al., 1989.)



ing the lateral angle of the frontal horn in its most rostral portion. Jürgens (1984) has observed direct connections from the SMA to the caudate. These mesial frontal cortex projections then spread to the ventral and lateral portion of the caudate and to the lateral portion of the putamen.

Thus, a lesion located in the most medial white matter surrounding the lateral angle of the most rostral portion of the frontal horn (medial ScF) would interrupt pathways from cingulate gyrus area 24 and the SMA into the caudate and putamen. This interruption would affect the initiation and preparation for speech movements and the limbic aspects of spontaneous speech.

M¹/₃ PVWM Area

The M¹/₃ PVWM area adjacent to the body of the lateral ventricle on CT scan slice SM is believed to contain, in part, the subcortical white matter fibers deep to the lower motor-sensory cortex area for the mouth. These PVWM pathways are diagrammed coronally in Fig. 12. The motor cortex projections for the mouth have recently been shown in an anterograde staining study with rhesus monkeys to project directly into the second quarter of the PVWM, adjacent to the body of the lateral ventricle (Schulz et al., 1993). Thus, the M¹/₃ PVWM area probably contains the motor-sensory projections for the mouth, immediately superior to their de-

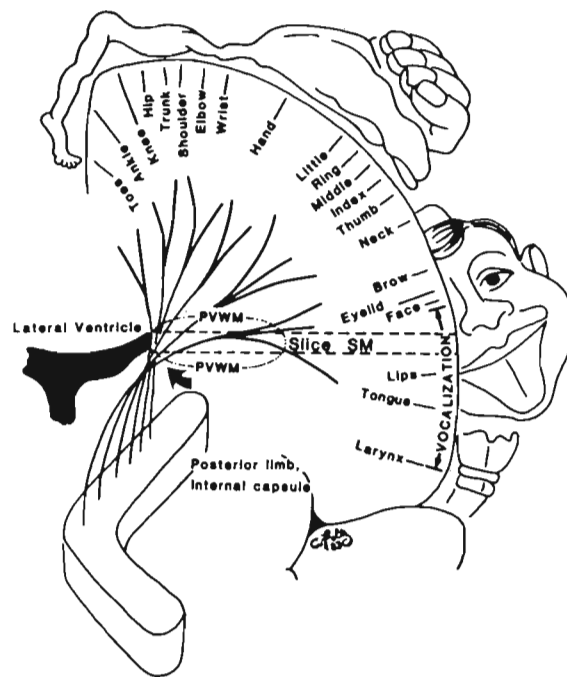


FIG. 12. Coronal diagram shows location of descending pyramidal tract pathways in the deepest, subcortical periventricular white matter (PVWM) area immediately adjacent to the body of the lateral ventricle (arrow). On CT scan, these descending pyramidal tract pathways are located in the second and third quarters of the PVWM on slices SM and SM + 1. On the CT scan slices inferior to SM and SM + 1 (W, B/W and B), the pyramidal tract pathways are located in the posterior limb of the internal capsule. (Reprinted from Naeser et al., 1989.)

scent into the genu of the internal capsule. In addition, the M $\frac{1}{3}$ PVWM area contains the body of the caudate nucleus and numerous other intra- and interhemispheric pathways. These pathways include the following, in part: (a) the descending pyramidal tract pathways for the leg and arm (Ross, 1980; Schulz et al., 1993); (b) the mid-callosal pathways; (c) additional medial subcallosal fasciculus pathways with connections from the SMA and cingulate gyrus to the body of the caudate (Muratoff, 1893; Dejerine, 1895; Yakovlev and Locke, 1961); (d) the occipitofrontal fasciculus (Dejerine, 1895); and (e) the superior lateral thalamic peduncle, which includes projections from the dorsomedial nucleus and the anterior nucleus to the cingulate (Mufson and Pandya, 1984) and projections from the ventrolateral nucleus to the motor cortex.

We hypothesize that lesion in the two deep subcortical white matter areas, the medial ScF area and the M $\frac{1}{3}$ PVWM area, combined effectively prevents any relevant spontaneous speech because there are no available pathways for speech initiation, motor execution, or sensory feedback.

It is important to understand that the presence or absence of hemiplegia is not always a useful marker in predicting potential for long-term recovery of spontaneous speech (Naeser et al., 1989). For example, the descending pyramidal tract pathways for the leg are most medial, within the second and third quarters of the PVWM area on CT scan and immediately adjacent to the body of the lateral ventricle (slices SM and SM + 1) (Schulz et al., 1993; Naeser et al., 1992). The descending pyramidal tract pathways for the arm are slightly more anterior and lateral within the PVWM. Thus, if the paralysis is due to lesion in the PVWM, it will be directly related to the depth of the PVWM lesion adjacent to the body of the lateral ventricle, assuming there is no lesion in the higher cortical motor pathways for the leg and arm or in the lower subcortical motor pathways for the leg and arm (internal capsule and brainstem) (Naeser et al., 1992).

A patient with no spontaneous speech may have a lesion in the medial ScF and in more than half of the M $\frac{1}{3}$ PVWM area, with no lesion in the deepest portion of the M $\frac{1}{3}$ PVWM area immediately adjacent to the body of the lateral ventricle, and have no paralysis. The CT scan of a patient without paralysis and with no spontaneous speech is shown in Fig. 8A [case 16 from Naeser et al. (1989)]. Thus, the severity of paralysis can be shown to relate to specific separate lesion sites, and the severity of the

spontaneous speech deficit can also be shown to relate to specific separate lesion sites. Therefore, recovery from paralysis is often a separate issue from recovery of spontaneous speech.

In summary, the cases with the least recovery of spontaneous speech, i.e., those with no speech or only stereotypies (groups 1 and 2), had total extent-of-lesion ratings >7 for the medial ScF area plus the M $\frac{1}{3}$ PVWM area. Those cases with better recovery of spontaneous speech, i.e., those with nonfluent Broca's aphasia (group 4), had total extent-of-lesion ratings <6 for the medial ScF area plus the M $\frac{1}{3}$ PVWM area. Those cases who fell in between these two groups in severity of impairment of spontaneous speech, i.e., those with a few words and/or some overlearned phrases, fell in between these two groups in terms of combined extent-of-lesion ratings (~6). There were exceptional cases at either extreme within group 3. A few case examples and CT scans are presented next.

Case Examples

Group 1

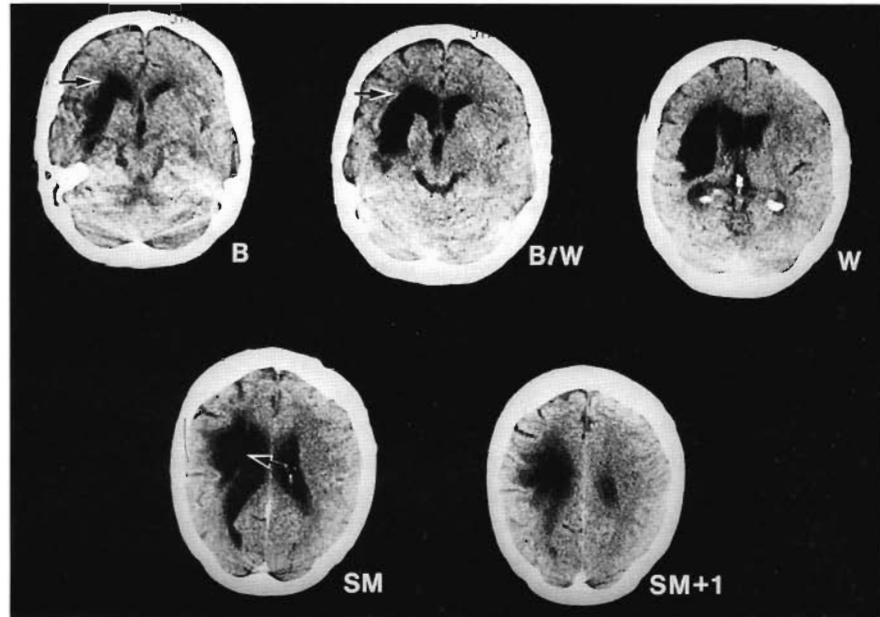
Patient 3 was a 35-year-old man. At 9 MPO, he still had no speech, although he could phonate and grunt. The CT scan from patient 3 in Fig. 13 shows a primarily subcortical infarct with extensive lesion in the medial ScF area at slices B and B/W and extensive lesion in the M $\frac{1}{3}$ PVWM area at slice SM. The total extent-of-lesion rating in these two areas was 9.95 (Fig. 13). On follow-up testing 5 years postonset, this patient continued to have no meaningful spontaneous speech. He had a dense right hemiplegia with poor recovery; the second- and third-quarter PVWM lesion was immediately adjacent to the body of the lateral ventricle at slice SM.

Patient 3 had aphasia with primarily subcortical lesion sites. He had no spontaneous speech output and a moderate comprehension deficit (-0.21 on the BDAE auditory comprehension Z score at 7 MPO); the moderate comprehension deficit was compatible with a lesion in the anterior subcortical temporal isthmus area on slice B/W.

Group 4

Patient 23, WA, was a 50-year-old man. At 7 MPO, he had partial recovery of speech, producing nonfluent, agrammatical speech compatible with Broca's aphasia. The CT scan from patient 23 in Fig. 14 shows an extensive lesion in the medial ScF area at slices B and B/W but only a minimal, small,

FIG. 13. CT scan 9 MPO from a 35-year-old man (patient 3) who had no speech 7 MPO or even 2 years later (Group 1). A dense right hemiplegia was present. The left-hemisphere lesion is on the left side of the CT scan. The extent-of-lesion rating for the medial ScF area at slice B was 5; at slice B/W, it was also 5 (arrows); mean, 5. The extent-of-lesion rating in the M $\frac{1}{3}$ PVWM area at slice SM was 4.95 (arrow); the total extent-of-lesion rating was 9.95. Note that the lesion is primarily subcortical. (Reprinted from Naeser et al., 1989.)



patchy lesion in the M $\frac{1}{3}$ PVWM at slice SM. The total extent-of-lesion rating in the two areas was 5.88 (Fig. 14). Mild hemiparesis was present, and there was good recovery (there was no lesion in the second and third quarters of the PVWM area immediately adjacent to the body of the lateral ventricle at slices SM and SM + 1).

This case had a typical lesion distribution associ-

ated with longer-lasting Broca's aphasia, which we have repeatedly observed in our laboratory; the Broca's aphasics included in this study were still nonfluent and agrammatic 7 months to 6 years following stroke onset. This lesion distribution usually includes infarction in parts of Broca's area, which extends across to the border of the frontal horn (including the medial ScF area at slices B and/or B/W);

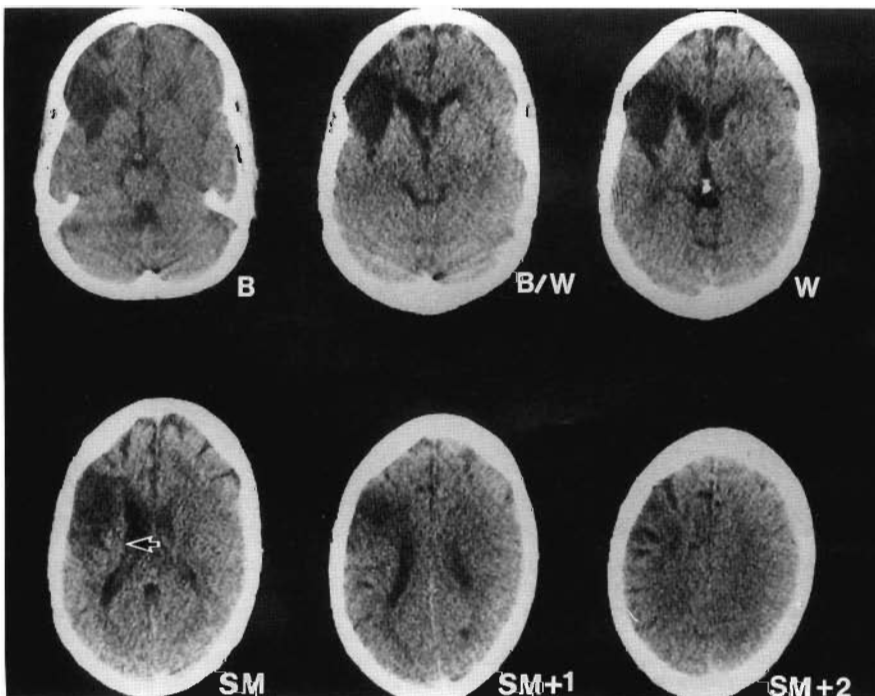


FIG. 14. CT scan at 44 MPO from a 54-year-old man (patient 23) who had nonfluent agrammatic speech and Broca's aphasia 7 MPO (Group 4). A mild hemiparesis was present and there was good recovery. The extent-of-lesion rating in the medial ScF area at slice B was 4; at slice B/W it was 3.75; mean, 3.88. The extent-of-lesion rating in the M $\frac{1}{3}$ PVWM area at slice SM was only 2; the total extent-of-lesion rating was 5.88. The arrow at slice SM shows the minimal lesion in the M $\frac{1}{3}$ PVWM area that greatly reduced the combined extent-of-lesion ratings to <6, a value compatible with the patient's mild limitations in speech. The mild hemiparesis with good recovery was compatible with sparing of the deepest PVWM area immediately adjacent to the body of the lateral ventricle at slices SM and SM + 1, which contains, in part, the descending pyramidal tract pathways. (Reprinted from Naeser et al., 1989.)

there is also superior lesion extension into the lower motor cortex area for mouth (slices W and SM), which extends into the deep, anterior one third ($A\frac{1}{3}$) of the PVWM area and sometimes into part of the $M\frac{1}{3}$ PVWM area (slice SM). In some cases, the lower motor cortex area lesion is absent (slices W and SM). The deep subcortical $A\frac{1}{3}$ PVWM lesion, however, is usually always present. The cortical portions of this lesion are compatible with lesion sites in longer-lasting Broca's aphasia cases previously published by Mohr et al. (1978).

Comparison of the CT scan for patient 3 (Fig. 13), who had no speech 9 MPO, with the CT scan for patient 23 (Fig. 14), who had nonfluent speech 7 MPO, reveals that the less severe case (patient 23) actually had more cortical damage (including damage in Broca's cortical area on slices B and B/W and in the lower motor cortex area for mouth on slice SM) than did the more severe case (patient 3), who had no cortical lesion in either Broca's cortical area or the lower motor cortex area for mouth. Comparison of the CT scans for these two cases suggests that it is the extent of lesion (degree of infarction) within the medial ScF and $M\frac{1}{3}$ PVWM areas that is related to the severity of speech output, not the extent of lesion within Broca's cortical area or other cortical areas. Patient 3, with no speech, had a complete lesion in the medial ScF area at slices B and B/W and a complete lesion in the $M\frac{1}{3}$ PVWM area at slice SM. Patient 23, with nonfluent speech, had a lesion in more than half of the medial ScF area at slices B and B/W but in only less than half of the $M\frac{1}{3}$ PVWM area at slice SM.

Broca's Original Case

The results from the 27 cases examined in Naeser et al. (1989) indicated that when extensive lesion was present in the medial ScF area and in the $M\frac{1}{3}$ PVWM area, there was poor recovery of spontaneous speech with no meaningful speech produced even 9 years poststroke. These results are further supported by examination of the CT scan of Broca's original aphasia patient, Leborgne.

Leborgne was 30 years old at the time of stroke onset, and he died 21 years later. His spontaneous speech was limited to the stereotypy "tan, tan." His auditory comprehension was reported to be good. He had a dense right hemiplegia. Broca attributed the poor speech to a lesion in the cortical region of the foot of the third left frontal convolution (Broca, 1861a, 1861b). Broca himself, however, never observed the depth of the lesion in Leborgne's brain. Recently a CT scan was performed on the preserved brain 140 years poststroke (Castaigne et al., 1980; Signoret et al., 1984). Figure 15 shows slices B/W, W, SM and SM + 1 of Leborgne's brain (no slice B was available). Examination of the deep subcortical white matter surrounding the lateral angle of the left frontal horn reveals extensive lesion in the medial ScF area at slice B/W, leading to the assumption that there was a similarly extensive lesion in the medial ScF area at slice B. There also is extensive lesion in the $M\frac{1}{3}$ PVWM area at slice SM. The total extent-of-lesion rating for the two areas combined was estimated to be 9, which is compatible with no long-term recov-

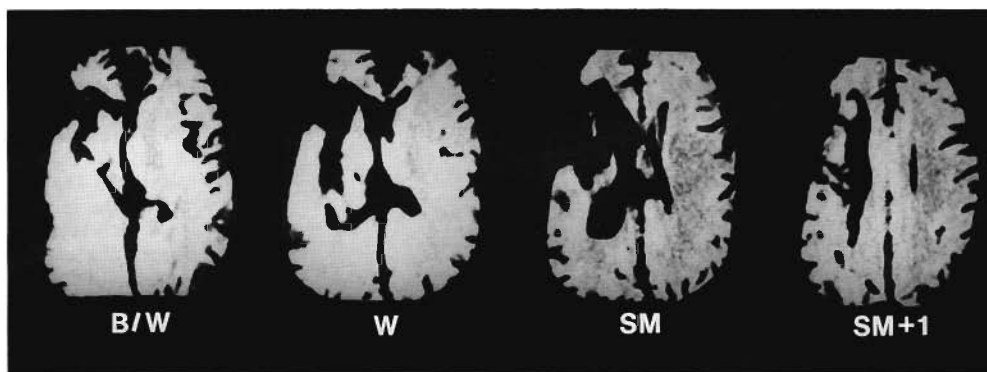


FIG. 15. CT scan of Broca's original case, Leborgne, from Castaigne et al. (1980). At 51 years old (21 years after stroke onset), Leborgne could produce only the stereotypy "tan, tan." This case was similar to the group 2 cases in the present study. A dense right hemiplegia was present. The extent-of-lesion rating in the medial ScF area at slice B/W was 5; although slice B was not available, it was assumed that because the lesion was so extensive on slice B/W, it was equally extensive on slice B and would rate a 5; thus, the mean rating for the medial ScF area was 5. The extent-of-lesion rating for the $M\frac{1}{3}$ PVWM area at slice SM was 4, so the total extent-of-lesion rating was 9. The total extent-of-lesion rating of 9 in these two deep subcortical white matter lesion site areas was well within the range for cases with severe limitation in speech (total extent-of-lesion ratings greater than 7). (Reprinted from Naeser et al., 1989.)

ery of spontaneous speech. The right hemiplegia may have been compatible with a lesion in the deepest PVWM at slice SM + 1, or possibly there was some lesion in the posterior-limb internal capsule at slice W.

Naeser et al. (1989) focused on spontaneous speech, and although all cases in groups 1 and 2 had severe limitations in spontaneous speech, not all had complete cessation of speech; 10 of 17 patients could still repeat a few words and 4 of 17 could correctly name some pictures on visual confrontation. Research by Kirzinger and Jürgens (1982) as well as others (Smith et al., 1981) has shown that a lesion in the SMA has a direct effect on initiation of "spontaneous" motoric behavior patterns that are triggered internally and not on those triggered by external stimuli. Kirzinger and Jürgens (1982) observed, for example, that after the SMA was ablated in squirrel monkeys and these monkeys were placed in isolation, the number of vocal "isolation calls" they emitted was reduced, although the acoustic structure remained intact. Thus, the absence of internally generated speech (spontaneous speech) in the presence of some externally generated speech (word repetition and naming) may be compatible, in part, with a lesion directly affecting projections from the SMA. Furthermore, variations in word repetition and naming ability observed across those subjects who otherwise had no meaningful spontaneous speech may have been partially due to variation in the extent of lesion in the projections from the SMA, as well as from other areas. This hypothesis would require further study.

Results from our study suggest that careful examination of lesions in the medial ScF area and the M $\frac{1}{3}$ PVWM area is a basic starting point for assessing potential for long-term recovery of spontaneous speech in severely nonfluent stroke patients with infarction in the various branches of the left-middle cerebral artery (LMCA). When working with patients who have lesions outside the LMCA, especially in the left-anterior cerebral artery (LACA), one must examine different structures. For example, in cases with LACA infarcts, it is possible that a direct cortical lesion in the SMA and/or the cingulate gyrus area may combine with a subcortical lesion in the M $\frac{1}{3}$ PVWM area to produce long-lasting impairment in speech, even when no lesion is present in the medial ScF area at slices B and B/W. Obviously, other cortical and/or subcortical lesion site combinations may produce severe limitations in speech or no speech.

LESION SITE ANALYSIS AND NONVERBAL TREATMENT

Almost 20 years ago, the first systematic attempts to utilize a substituted "language" based on representational and arbitrary icons were reported (Baker et al., 1975; Gardner et al., 1976). More recently, that iconic language has been further developed and adapted for use on a minicomputer (Steele et al., 1989; Weinrich et al., 1989*a,b*). Investigators have demonstrated that severely aphasic patients can manipulate the computer mouse and button-click necessary for operation and can learn the rules of lexical organization. The computer-assisted visual communication treatment program enables patients with no spontaneous speech (or ability to read or to write) to use pictures and icons on a computer screen to communicate their needs and ideas (Fig. 16).

The patients learn to construct and comprehend complex sentences in the C-ViC pictorial language. Not all severely aphasic patients, however, have been able to grasp the lexical and syntactic rules of the substituted language and to use them to initiate communication independently.

The relationship between CT scan lesion sites and good response to C-ViC (ability to independently initiate communication with C-ViC) versus poor response to C-ViC (inability to independently initiate communication with C-ViC) was examined in seven severe-aphasia patients with no ability to speak, read, or write (Palumbo et al., 1992). These patients were treated with C-ViC beginning in the chronic phase poststroke. All seven patients had suffered left-hemisphere cerebrovascular accidents. Age at onset of stroke ranged from 43 to 65 years (mean, 56; SD, 7.5). One patient was left-handed. All seven patients had severe right hemiplegia.

The Boston Assessment of Severe Aphasia test (BASA) (Helm-Estabrooks et al., 1989) was performed immediately prior to C-ViC training and again at its termination. The BASA test was designed for severely aphasic patients and probes for even small improvements in auditory comprehension or language production. Most patients were also tested with parts of the Boston Diagnostic Aphasia Exam (Goodglass and Kaplan, 1983). Aphasia diagnosis prior to C-ViC treatment was "severe aphasia with no spontaneous output—spoken or written—in conversation or picture description." Auditory comprehension was also substantially impaired. Table 1 summarizes language capacity.




FIG. 16. A: A severe nonverbal aphasia patient using the Computer-assisted Visual Communication (C-ViC) program on the Macintosh computer. The patient has a right hemiplegia, and controls the "mouse" with the non-paralyzed left hand to select pictures and icons on the computer screen. B: Example of communication generated by a nonverbal aphasia patient in Phase II of the C-ViC program. The patient's spouse has said that they ate at a fish restaurant over the weekend. The clinician asked, "When you were at the restaurant, who cut your food for you?" The patient generated the above response using C-ViC. The C-ViC program is customized to individual patient needs, including photos of family members and hospital staff. The written English is not usually provided below each picture or icon, because this tends to confuse the patient who cannot read or write. The written English is provided here only for purposes of illustration. (Reproduced with permission.)

TABLE 1. Patient data and language test scores for patients treated with the computer-assisted visual communication program (C-ViC)

Patient	Sex	Age at onset (y)	MPO when C-ViC started	Months in treatment	BDAE		BASA			C-ViC response, Phase II, step 5, PICA scale (maximum, 16)
					No. words per phrase (maximum, 7)	Auditory comprehension Z score	Overall score (maximum, 61)	Auditory comprehension raw score (maximum, 16)	Oral-gestural expression raw score (maximum, 21)	
Good response										
BJ	M	43	7	3	0	-0.8	49	13	14	15.0
Pre					1-2	+0.5	51	14	14	
DJ	M	54	6	6	0	-1.75	36	8	9	14.5
Pre					0	NA	39	7	14	
SH	F	65	4	18	0	NA	26	7	3	14.0
Pre					0	NA	37	10	5	
CA	M	49	72	9	0	-0.63	40	13	7	12.5
Pre					0	NA	40	13	8	
Poor response										
RR	M	59	21	28	0	-0.61	25	6	3	9.0
Pre					0	NA	38	6	13	
FW	M	59	7	7	0	-1.6	31	9	6	8.5
Pre					0	-0.33	41	13	7	
SM	M	60	60	7	0	-1.74	24	4	7	8.0
Pre					0	-1.61	29	8	7	

Patients are rank ordered by response to Phase II, step 5, of the C-ViC program. Scores ≥ 13 reflect ability to initiate communication independently with the C-ViC program; scores of 8-9 reflect inability to initiate a question or command. Patient BJ is left-handed but aphasic from a lesion in the left hemisphere. Pre, before C-ViC treatment; post, after C-ViC treatment.

All seven patients had been previously treated with one or more traditional treatment programs without success, including verbal treatment programs such as melodic intonation therapy (Albert et al., 1973; Sparks and Holland, 1976), nonverbal treatment programs such as buccofacial visual action therapy, which trains patients with severe oral apraxia to produce representational gestures using the oral musculature (Ramsberger and Helm-Estabrooks, 1988), and/or limb visual action therapy, which trains patients with severe aphasia and limb apraxia to produce representational, purposeful gestures with the hand and arm (Helm-Estabrooks et al., 1982).

C-ViC Treatment Program

All patients were treated with C-ViC in the chronic phase poststroke (>3 MPO; range, 4 MPO to 6 years). Patients were seen as outpatients for half-hour treatment sessions, usually twice a week. All patients were able to match objects to pictured icons on a computer screen (and vice versa), and all were able to use the computer mouse easily with the left hand.

The C-ViC training consists of two phases (Baker and Nicholas, in press). In Phase I, patients are trained to use the mouse to carry out commands presented in C-ViC and answer questions (comprehension) and to compose descriptions of simple acts (production). Phase II focuses on real-life communicative acts, including expressing needs, making requests (giving commands), and asking questions (Fig. 16). Variability in duration of C-ViC treatment resulted from on-going program development as well as patient availability; the C-ViC training now lasts ~9 months, including completion of Phase II training.

The quality of the communications generated by patients using C-ViC in Phase I and Phase II were rated by clinicians using the Porch Index of Communicative Ability (PICA) rating scale, which ranges from 1 to 16 (Porch, 1967). A PICA score ≥ 13 represents independently initiated successful communication. Scores >13 were considered good C-ViC productions; scores <13 were considered poor C-ViC productions.

To reach criterion at the end of Phase I and to be considered a "good-response" case at the end of Phase II, the patient's communications generated with C-ViC must reach scores of at least 13 on the PICA scale. A patient with a Phase II C-ViC score of <13 is considered to be a "poor-response" case.

Three patients had a good response, with Phase II scores of 14–15; one patient had a borderline good response, with a score of 12.5; and three patients had poor response, with scores of 8–9 (Table 1).

There was no significant correlation between the age at stroke onset and the Phase II C-ViC score ($r = -0.482$) or between the MPO when entering the C-ViC program and the Phase II C-ViC score ($r = -0.352$). There was also no significant correlation between the number of months a patient received the C-ViC program and the Phase II C-ViC score ($r = -0.275$).

One of the patients who had a good response with C-ViC (patient SH) was able to remain at home with her spouse, versus transferring to a nursing home, as a result of her new communication ability with C-ViC. As a result of this patient's success with the C-ViC program, a Macintosh computer was placed in her home, and the patient used the system to communicate her needs to her husband, such as when she felt her prescriptions needed to be refilled.

Even patients with a poor response to C-ViC by PICA scoring were able to use C-ViC for some interactions not possible with speech or writing. Patient RR was considered to have a poor response to C-ViC because he was not able to initiate communications independently with C-ViC following Phase II training. He was, however, able to use C-ViC to answer specific questions posed by another person. Patient RR now has a Macintosh computer in his home, and he can use it to respond to his wife's verbally presented question, "What do you want for breakfast?"

The pre C-ViC BASA scores had a general correspondence to good response versus poor response with C-ViC. The four good-response patients had pre-C-ViC overall BASA scores of at least 26 correct items out of the total possible 61 items; two of the three poor-response patients had pre-C-ViC overall BASA scores of <26 (Table 1). The four good-response patients had pre-C-ViC auditory comprehension BASA subtest scores of at least 7 correct items out of the total possible 16 items; two of the three poor-response patients had pre-C-ViC auditory comprehension BASA subtest scores of <7 (Table 1). Thus, good response with C-ViC may be compatible with pre-C-ViC overall BASA scores of at least 26 and pre-C-ViC auditory comprehension BASA subtest scores of at least 7.

CT scan lesion site analysis was performed; the cortical and subcortical areas examined for extent-

of-lesion ratings are shown in Fig. 1B. The CT scans used for the lesion site analysis had been performed 3–36 MPO.

Relationship Between CT Scan Lesion Sites and Response to C-ViC Treatment

There was no relationship between good response or poor response to C-ViC treatment and lesion extent in any single neuroanatomical area analyzed on CT scan. Naeser et al. (1989) had observed that extensive lesion in the medial ScF area *plus* the M $\frac{1}{3}$ PVWM area combined was compatible with no recovery of spontaneous speech. In fact, all seven cases in this C-ViC study had total extent-of-lesion ratings >7 for the medial ScF area and the M $\frac{1}{3}$ PVWM area combined (Table 2). The good-response and poor-response patients had a complete overlap of total extent-of-lesion ratings in these two white matter areas.

Only one combination of additional lesion extension in two extra areas completely separated all good-response cases from all poor-response cases treated with C-ViC: the supraventricular area, including the SMA and cingulate gyrus area 24 near the vertex, *and* the temporal lobe area, including Wernicke's area or the subcortical temporal isthmus area (deep to Wernicke's area). The poor-response patients had extensive lesion (extent-of-lesion ratings >3) in *each* of these two extra areas.

The good-response patients had extensive lesion (extent-of-lesion ratings >3) in none or only one of these two extra areas (Table 2).

Case Examples

The CT scan for a nonverbal patient who had a good response to C-ViC training is shown in Fig. 17, and the CT scan for a nonverbal patient who had a poor response is shown in Fig. 18.

The results of our study suggest that CT scan lesion site analysis may be useful in identifying severe nonverbal aphasia patients who will probably not recover spontaneous speech, but who can be trained to communicate with the nonverbal C-ViC program. Patients with total extent-of-lesion ratings >7 for the medial ScF area *plus* the M $\frac{1}{3}$ PVWM area appear to be among the most appropriate patients for treatment with C-ViC.

Furthermore, patients with extensive lesion in both the supraventricular area, including the SMA and cingulate gyrus area 24 near the vertex, *and* the temporal lobe area, including Wernicke's area or the subcortical temporal isthmus area, appear to be unable to initiate communication independently with C-ViC. They require assistance, such as repeated cues or repeated instructions.

Although some patients have a poor response to C-ViC, they should still be trained to use C-ViC. The term "poor response" refers to communica-

TABLE 2. CT scan lesion sites and extent-of-lesion values for patients treated with the computer-assisted visual communication program (C-ViC)

Patient	CT scan (mo postonset)	Medial ScF (mean of slices B and B/W)	M $\frac{1}{3}$ PVWM (slice SM)	Total extent of lesion m ScF and M $\frac{1}{3}$ PVWM	"Extra" areas					
					Supraventricular		Temporal lobe		Right hemisphere lesion	Occipital length asymmetry
					Supplementary motor area	Cingulate gyrus area 24	Wernicke's area (mean of slices B/W and W)	Temporal isthmus (mean of slices B and B/W)		
Good response										
BJ	12	5	4.9	9.9	0	0	0	0	No	E
DJ	13	5	4.25	9.25	Deep	Deep	1	0	No ^a	E
SH	6	4.9	4.75	9.65	0	0	3.25	4.37	No	R
CA	72	3.5	5	8.5	0	0	4.55	4.5	No ^b	R
Poor response										
RR	49	4.75	4.9	9.65	Cortical and deep	Cortical and deep	2.5	4.5	No	L
FW	13	4.25	5	9.25	Cortical and deep	Cortical and deep	2.37	4.37	No	R
SM	60	2.37	4.75	7.12	Deep	Deep	4.9	5	No	L

For significance of ratings and explanation of "extra" areas, see text. Patient BJ was left-handed but aphasic from a lesion in the left hemisphere. E, equal; R, right occipital length was longer; L, left was longer.

^a Patchy low-density areas surrounding the anterior and posterior borders of the body of the lateral ventricle were present in the right hemisphere.

^b Shunt in right ventricle.

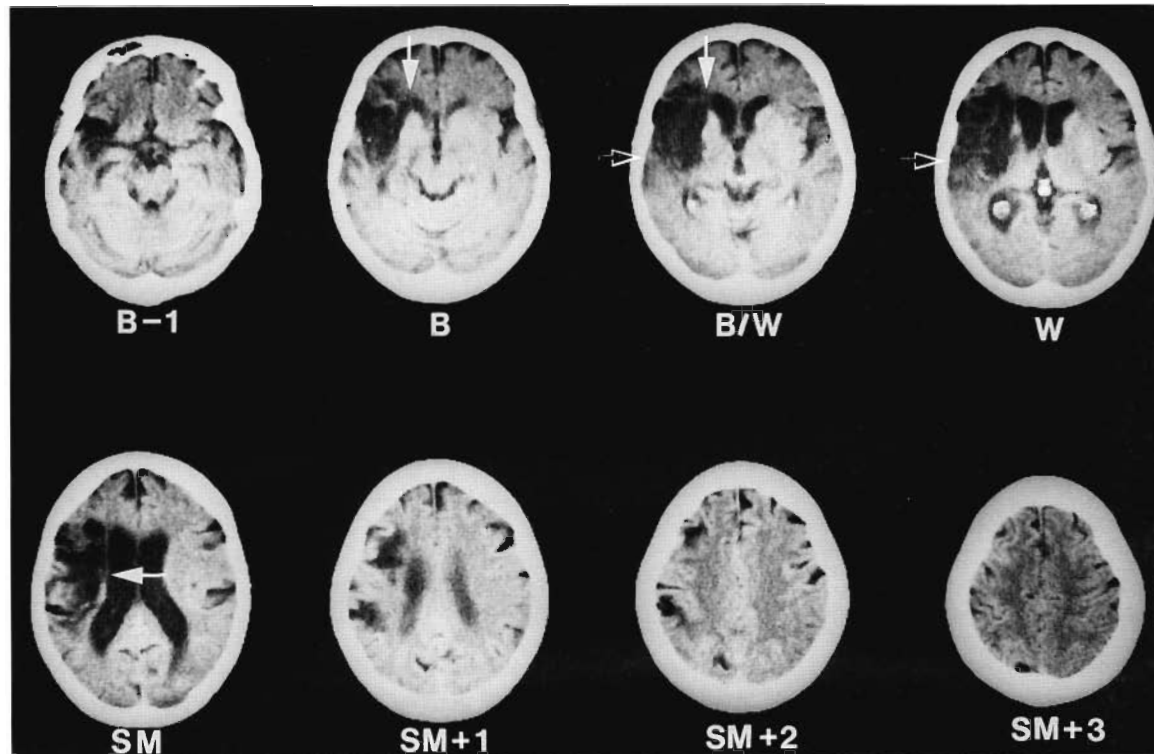


FIG. 17. CT scan for patient SH, a 65-year-old woman, who entered the C-ViC program at 4 MPO and had good response to the C-ViC treatment program. The basic lesion site pattern associated with no recovery of spontaneous speech was present in the medial ScF area on slices B and B/W (white arrows), plus the M $\frac{1}{3}$ PVWM area on slice SM (white arrow). The total extent-of-lesion rating for medial ScF area plus M $\frac{1}{3}$ PVWM area was 9.65. In addition, extensive lesion was present in only *one* of the two extra areas. Lesion was present in the temporal lobe area, including Wernicke's area on slices B/W and W (black and white arrows) and the subcortical temporal isthmus area on slices B-1 and B. No lesion was present in the supraventricular area, including the SMA and cingulate gyrus on slices SM + 2 and SM + 3. The CT scan was done 6 MPO.

tions that are rated below 13 on the PICA scale plus an inability to initiate communications independently with C-ViC at the Phase II level. The expectations of outcome with the C-ViC program can be lowered to accommodate patients who can use C-ViC, with assistance, to answer specific questions. Thus, practical use of C-ViC in the home, nursing home, or rehabilitation setting should be determined on a case-by-case basis.

Sarno and Levita (1981) have observed that the greatest recovery in severe aphasia patients occurs 6–12 MPO. Therefore, it seems likely that with a severe, nonverbal aphasia patient, a chronic CT scan could be obtained 3 MPO, and the results could be used to help with treatment decisions for the 6–12-MPO treatment period and beyond. Of course, other treatment approaches should be used earlier, including helping the patient to use a basic communication board, drawing (Morgan and Helm-Estabrooks, 1987), or gesture (Skelly et al., 1974, 1975; Rao, 1986).

Careful analysis of a chronic CT scan may help reduce the overall cost in long-term rehabilitation of severe, nonverbal aphasia patients by helping to identify potential for recovery (or nonrecovery) of spontaneous speech. There are several factors that should be considered; (a) the more complete borders of an infarct are best visualized on CT scans performed 2–3 MPO; acute CT scans performed earlier do not reveal the more complete borders of an infarct and do not help to make predictions for long-term recovery; (b) to use the information in this article, the CT scan should be obtained at 20° to the canthomeatal line, without contrast, with 10-mm slice thickness at 7-mm intervals above the suprasellar cistern and through the ventricles; CT scans performed in this manner will conform to the CT scan slice images shown in Fig. 1B, and the medial ScF area and the M $\frac{1}{3}$ PVWM area, as well as Wernicke's area and the temporal isthmus, can be easily located for detailed extent-of-lesion analysis; and (c) if the total extent-of-lesion rating for

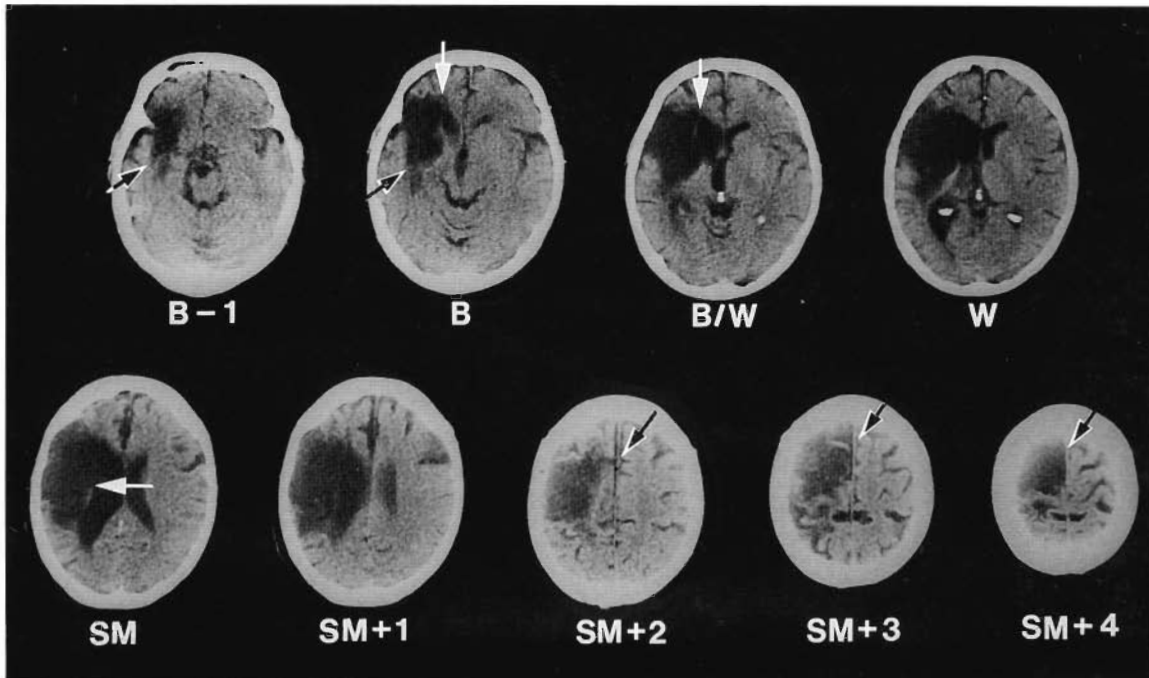


FIG. 18. CT scan for patient RR, a 60-year-old man who entered the C-ViC program 21 MPO and had a poor response to C-ViC treatment. The basic lesion site pattern associated with no recovery of spontaneous speech was present in the medial ScF area on slices B and B/W (white arrows), plus the $M\frac{1}{3}$ PVWM area on slice SM (white arrow). The total extent-of-lesion rating for medial ScF area plus the $M\frac{1}{3}$ PVWM area was 9.65. In addition, extensive lesion was present in both the supraventricular area including SMA/cingulate gyrus area (black and white arrows) and the temporal lobe area, including the subcortical temporal isthmus area on slices B-1 and B (black and white arrows). The CT scan was done 4 years postonset.

the medial ScF area and the $M\frac{1}{3}$ PVWM area is >7 , then it is unlikely the patient will recover spontaneous speech; for such patients, a nonverbal treatment program might be considered, such as C-ViC. If the extent-of-lesion rating is >3 for none or only one of the two extra areas observed in the C-ViC study, then the nonverbal patient will probably have a good response with C-ViC and probably will be able to initiate communication independently with C-ViC. The two extra areas on CT scan that must be examined regarding potential for good response with C-ViC are the supraventricular area, including the SMA and cingulate gyrus area 24 near the vertex, and the temporal lobe area, including Wernicke's area or the anterior subcortical temporal isthmus area. If the extent of lesion is >3 for *each* of these two extra areas, then the nonverbal patient will probably have a poor response with C-ViC, although he or she may be able to answer simple questions with C-ViC.

LESION SITE ANALYSIS ON MRI SCANS

MRI scans are excellent at showing the presence of an infarction within 48 h of stroke onset (Bydder

et al., 1982; Buonanno et al., 1983; DeWitt et al., 1984; Sipponen, 1984), although the infarction is better visualized on MRI scans performed 3 MPO than on MRI scans performed 1 MPO (Alexander et al., 1991). Even chronic MRI scans performed 3 MPO, however, present unique problems regarding application of the method of lesion site analysis presented in this article.

We have observed discrepancies in the depth of lesion between MRI scans and CT scans especially near ventricle and near the frontal horn. We have also observed discrepancies in the depth of lesion near ventricle between T1-weighted MRI images and T2-weighted MRI images. A case example showing some of these discrepancies is presented in Figs. 19 and 20. The patient (SJ) was a 51-year-old man, who was examined 3 years postsurgery for an aneurysm. This patient produced no substantive words for the BDAE cookie theft picture description—i.e., he had no meaningful spontaneous speech 3 years postonset. Based on the CT scan material presented earlier, the patient would be expected to have extensive lesion in the medial ScF area on slices B and B/W and in the $M\frac{1}{3}$ PVWM area on slice SM.

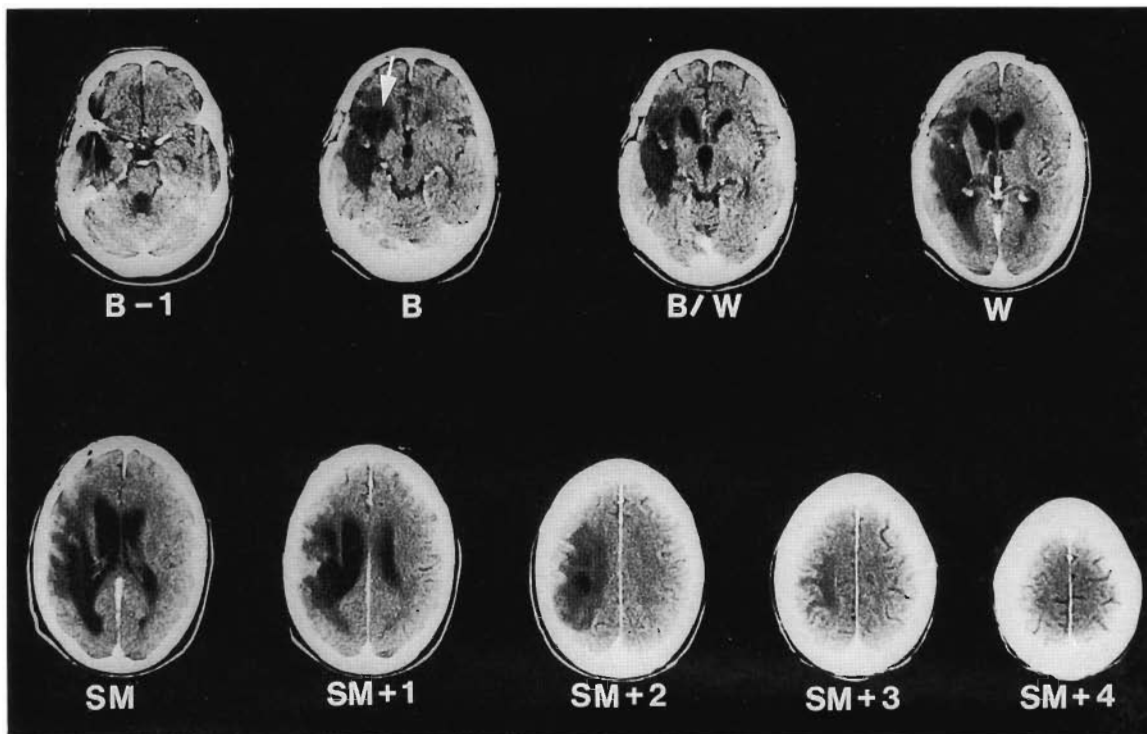


FIG. 19. CT scan for patient SJ, performed 3 years postsurgery for an aneurysm. SJ had no spontaneous speech 3 years postonset. This CT scan shows extensive lesion in the medial ScF area on slice B and slice B/W. In fact, the medial ScF lesion is so deep on slice B that it touches the frontal horn (arrow). The extent of lesion rating for the medial ScF on slice B was 4.9 (almost completely solid lesion), and the rating for the medial ScF area on slice B/W was 3.5 (patchy—more than half of the area has lesion); the mean extent-of-lesion rating for the medial ScF area was 4.2. The extent-of-lesion rating for the $M\frac{1}{3}$ PVWM area on slice SM was 3 (lesion in half of the area). The total extent-of-lesion rating for these two subcortical areas on CT scan was 7.2—i.e., a rating compatible with no recovery of meaningful spontaneous speech. (CT scan slice thickness was 10 mm, performed at 7-mm intervals.)

Figure 19 shows the CT scan for this patient performed 3 years postonset. The scan shows extensive lesion in the medial ScF area on slice B and slice B/W. In fact, the medial ScF lesion is so deep on slice B that it touches the frontal horn. The extent-of-lesion rating for the medial ScF area on slice B was 4.9 (almost completely solid lesion) and the extent-of-lesion rating for the medial ScF area on slice B/W was 3.5 (patchy—more than half of the area has lesion). The mean extent-of-lesion rating for the medial ScF area across slices B and B/W was 4.2. The extent-of-lesion rating for the $M\frac{1}{3}$ PVWM area on slice SM was 3 (lesion in half of the area). The total extent-of-lesion rating for these two subcortical areas on CT scan was 7.2—i.e., a rating compatible with no recovery of meaningful spontaneous speech. (CT scan slice thickness was 10 mm, performed at 7-mm intervals.)

Figure 20A shows the T1-weighted MRI images (TR, 600; TE, 20 ms) for SJ, also performed 3 years postonset. These T1-weighted, horizontal, axial images do not show the lesion in the medial ScF area

to touch the frontal horn on either of the first two MRI slices. (MRI slice thickness was 5 mm, with a 2.5-mm gap.) The extent-of-lesion ratings for the medial ScF area on the first two slices showing frontal horn on the T1-weighted MRI images would be only 0 or 1 (compared with 4.9 and 3.5, respectively, on the first two slices showing frontal horn on the CT scan images). It has been our observation that the T1-weighted images underestimate the borders of the lesion, especially near the ventricle, compared with chronic CT scans performed at the same time postonset (Naeser and Palumbo, in press; Naeser et al., in preparation).

Figure 20B shows the T2-weighted MRI images (TR, 2,000; TE, 80 ms) for SJ, also performed 3 years postonset. These T2-weighted, horizontal, axial images do show the lesion in the medial ScF area to touch the frontal horn on both of the first two slices. The depth of lesion in the medial ScF area on these T2-weighted MRI images is not in agreement with the depth of lesion in the medial ScF area on the T1-weighted MRI images. If only

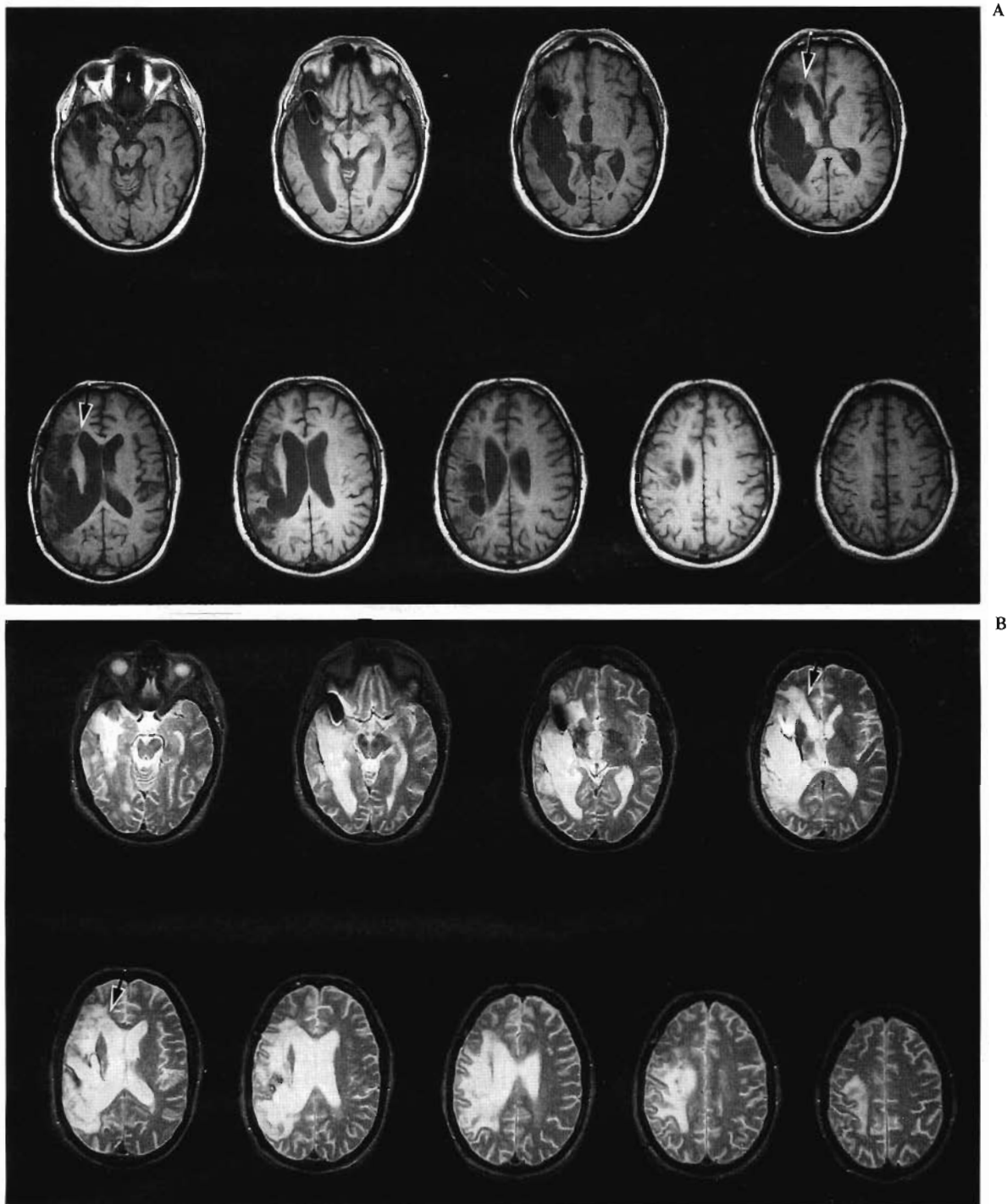


FIG. 20. **A:** T1-weighted MRI images (TR, 600; TE, 20 ms) for patient SJ, performed 3 years postonset. These horizontal axial images do not show the lesion in the medial ScF area to touch the frontal horn on either of the first two slices where frontal horns are present (arrows). (MRI slice thickness was 5 mm, with a 2.5-mm gap.) The extent-of-lesion rating for the medial ScF area on the first two slices of these T1-weighted MRI images would be only 0 or 1. It has been our observation that T1-weighted images underestimate the borders of the lesion, especially near the ventricle, compared with a chronic CT scan performed at the same time postonset (Naeser et al., in preparation). **B:** T2-weighted images (TR, 2,000; TE, 80 ms) for patient SJ, performed 3 years postonset. These horizontal axial images *do* show the lesion in the medial ScF area to touch the frontal horn on both of the first two slices where frontal horns are present (arrows). The depth of the lesion in the medial ScF area on these T2-weighted MRI images is not in agreement with the depth of the lesion in the medial ScF area on the T1-weighted MRI images. If only the T1-weighted and the T2-weighted MRI images were performed and no CT scan images were performed, we would not know which set of MRI images to use for the extent-of-lesion rating analysis. We have observed that the T2-weighted MRI images tend to exaggerate the borders of the lesion, especially near the ventricle.

the T1-weighted and T2-weighted MRI images were performed, with no CT scan, we would not know which set of MRI images to use for the extent-of-lesion rating analysis. We have observed that the T2-weighted MRI images tend to exaggerate the borders of the lesion, especially near the ventricle. Proton-density MRI images (TR, 2,000; TE, 30 ms) also tend to exaggerate the borders of the lesion, especially near the ventricle (Naeser and Palumbo, in press; Naeser et al., in preparation).

Research from other laboratories has shown that T2-weighted MRI images of chronic infarcts reveal borders that are larger than the actual areas of infarct as revealed by pathology (DeWitt et al., 1985). Black et al. (1984) have also observed larger areas of infarction on T2-weighted MRI images than on chronic CT scans.

In summary, the method of lesion site analysis presented in this article is best applied only to CT scans that have been performed 3 MPO, for the following reasons: (a) chronic T1-weighted MRI images tend to underestimate the borders of the lesion in relationship to the borders of the lesion on chronic CT scans (especially near ventricle), and (b) chronic T2-weighted MRI images tend to exaggerate the borders of the lesion (especially near ventricle).

Acknowledgment: The authors acknowledge Malee Nolle Prete for assistance in CT scan analysis and data collection and Claudia Cassano and Roger Ray for assistance with manuscript preparation. We also thank the Radiology Service of the Boston VA Medical Center, including Drs. A. Robbins and R. N. Samaraweera, and the Medical Media Service (John Dyke and Mary Burke), Boston VA Medical Center, for photography and illustrations. Research supported in part by Medical Research Service of the Department of Veterans Affairs and by USPHS Grant DC00081.

REFERENCES

- Albert ML, Sparks R, Helm N. Melodic intonation therapy for aphasia. *Arch Neurol* 1973;29:130-31.
- Alexander MP, Naeser MA, Palumbo CL. Correlations of subcortical CT lesion sites and aphasia profiles. *Brain* 1987;110:961-91.
- Alexander MP, Naeser M, Sweriduk S. Comparison of lesion profiles with CT and early and late MRI: implications for aphasia research. Presented at the 29th Annual Meeting of the Academy of Aphasia, Rome, Italy, October 1991.
- Baker E, Berry T, Gardner H, Zurif E, Davis L, Veroff A. Can linguistic competence be dissociated from natural language functions? *Nature* 1975;254:609-19.
- Baker EH, Nicholas M. *Computer-assisted visual communication C-ViC for severe nonverbal aphasia patients: a training manual*. *Am J Speech Lang Pathol* (in press).
- Barnes CL, Van Hoesen GW, Yeterian EH. Widespread projections to the striatum from the limbic mesocortices in the monkey. *Soc Neurosci Abstr* 1980;6:271.
- Benjamin D, Van Hoesen GW. Some afferents of the supplementary motor area (SMA) in the monkey. *Anat Rec* 1982;202:15A.
- Black S, Kertesz A, Nicholson L. Increased signal intensity in the border zone of chronic infarcts detected by T2-weighted NMR imaging. *Neurology* 1984;34:116.
- Bogen JE, Bogen GM. Wernicke's region: where is it? *Ann NY Acad Sci* 1976;280:834-43.
- Borod JC, Carper M, Goodglass H, Naeser M. Aphasic performance on a battery of constructional, visuospatial, and quantitative tasks: factorial structural and CT scan localization. *J Clin Neuropsychol* 1984;6:189-204.
- Broca P. Perte de la parole; ramollissement chronique et destruction partielle du lobe antérieur gauche du Cerveau. *Bull Soc Anthropol Paris* 1861a;2:235-8.
- Broca P. Remarques sur le siège de la faculté du langage articulé, suivies d'une observation d'aphémie (Perte de la parole). *Bull Soc Anat Paris* 1861b;36:330-57.
- Buonanno FS, Kistler JP, DeWitt LD, Pykett IL, Brady TJ. Proton (¹H) nuclear magnetic resonance (NMR) imaging in stroke syndromes. *Neurol Clin* 1983;11:243-62.
- Bydder GM, Steiner RE, Young IR, et al. Clinical NMR imaging of the brain: 140 cases. *Am J Radiol* 1982;139:215-36.
- Castaigne P, Lhermitte F, Signoret JL, Abelanet R. Description et étude scannographique du cerveau de Leborgne: la découverte de Broca. *Rev Neurol* 1980;136:563-83.
- DeArmond SJ, Fusco MM, Dewey MM. *Structure of the human brain: a photographic atlas*. 2nd ed. New York, London: Oxford University Press, 1976.
- Dejerine J. *Anatomie des centres nerveux*. Vol 1. Paris: Rueff, 1895.
- DeWitt LD, Buonanno FS, Kistler JP, et al. Nuclear magnetic resonance imaging in evaluation of clinical stroke syndromes. *Ann Neurol* 1984;16:535-45.
- DeWitt LD, Kistler JP, Miller DC, Richardson EP, Buonanno FS. NMR-neuropathologic correlation in stroke. *Stroke* 1985;16:151.
- Gardner H, Zurif E, Berry T, Baker E. Visual communication in aphasia. *Neuropsychologia* 1976;14:275-92.
- Goldberg G. Supplementary motor area structure and function. Review and hypothesis. *Behav Brain Sci* 1985;8:567-615.
- Goodglass H, Kaplan E. *The assessment of aphasia and related disorders*. Philadelphia: Lea & Febiger, 1972.
- Goodglass H, Kaplan E. *Assessment of aphasia and related disorders*. 2nd ed. Philadelphia: Lea & Febiger, 1983.
- Hanaway J, Scott WR, Strother CM. *Atlas of the human brain and the orbit for computed tomography*. St. Louis: Green, 1977.
- Helm-Estabrooks N, Fitzpatrick P, Barresi B. Visual action therapy for global aphasia. *J Speech Hearing Disord* 1982;47:385-9.
- Helm-Estabrooks N, Ramsberger G, Morgan A, Nicholas M. *Boston assessment of severe aphasia*. San Antonio: Special Press, 1989.
- Hier DB, Davis KR, Richardson EP, Mohr JP. Hypertensive putaminal hemorrhage. *Ann Neurol* 1977;11:152-9.
- Jernigan TL, Zatz LM, Naeser MA. Semiautomated methods for quantitating CSF volume on cranial computed tomography. *Radiology* 1979;132:463-6.
- Jürgens U. The efferent and afferent connections of the supplementary motor area. *Brain Res* 1984;300:63-81.
- Kertesz A. *Aphasia and associated disorders: taxonomy, localization and recovery*. New York, London: Grune & Stratton, 1979.
- Kertesz A, Harlock W, Coates R. Computer tomographic localization, lesion size, and prognosis in aphasia and nonverbal impairment. *Brain Lang* 1979;8:34-50.

- Kirzinger A, Jürgens U. Cortical lesion effects and vocalization in the squirrel monkey. *Brain Res* 1982;233:299-315.
- Matsui T, Hirano A. *An atlas of the human brain for computerized tomography*. Tokyo: Igaku-Shoin, 1978.
- Mohr JP, Pessin MS, Finkelstein S, et al. Broca aphasia: pathologic and clinical. *Neurology* 1978;28:311-24.
- Morgan A, Helm-Estabrooks N. Back to the drawing board: a treatment program for nonverbal aphasic patients. In: Brookshire RH, ed. *Clinical aphasiology conference proceedings*. Minneapolis: BRK Publishers, 1987:64-72.
- Mufson EJ, Pandya DN. Some observations on the course and composition of the cingulum bundle in the rhesus monkey. *J Comp Neurol* 1984;225:31-43.
- Muratoff W. Secundäre Degeneration nach Durchschneidung des Balkens. *Neurol Centralblatt* 1893;12:714-29.
- Naeser MA. CT scan lesion size and lesion locus in cortical and subcortical aphasia. In: Kertesz A, ed. *Localization in neuropsychology*. New York: Academic Press, 1983:63-119.
- Naeser MA, Alexander MP, Helm-Estabrooks N, Levine HL, Laughlin SA, Geschwind N. Aphasia with predominantly subcortical lesion sites—description of three capsular/putaminal aphasia syndromes. *Arch Neurol* 1982;39:2-14.
- Naeser MA, Alexander MP, Palumbo CL, Samaraweera RN, Sweriduk S. Comparison of white matter infarcts on chronic CT scans versus chronic MRI scans: why chronic CT scans correlate better with recovery of speech in aphasia. (in preparation).
- Naeser MA, Alexander MP, Stiassny-Eder D, Galler V, Hobbs J, Bachman D. Real versus sham acupuncture in the treatment of paralysis in acute stroke patients—a CT scan lesion site study. *J Neurol Rehabil* 1992;6:163-73.
- Naeser MA, Gaddie A, Palumbo CL, Stiassny-Eder D. Late recovery of auditory comprehension in global aphasia: improved recovery observed with subcortical temporal isthmus lesion versus Wernicke's cortical area lesion. *Arch Neurol* 1990;47:425-32.
- Naeser MA, Hayward RW. Lesion localization in aphasia with cranial computed tomography and the Boston Diagnostic Aphasia Exam. *Neurology* 1978;28:545-51.
- Naeser MA, Hayward RW, Laughlin SA, Becker JMT, Jernigan TL, Zatz LM. Quantitative CT scan studies in aphasia II: comparison of the right and left hemispheres. *Brain Lang* 1981;12:165-89.
- Naeser MA, Helm-Estabrooks N, Haas G, Auerbach S, Srinivasan, M. Relationship between lesion extent in "Wernicke's area" on CT scan and predicting recovery of comprehension in Wernicke's aphasia. *Arch Neurol* 1987;44:73-82.
- Naeser MA, Palumbo CL. How to analyze CT/MRI scan lesion sites to predict potential for long-term recovery in aphasia. In: Kirschner H, ed. *Handbook of neurologic speech and language disorders*. New York: Marcell Dekker (in press).
- Naeser MA, Palumbo CL, Helm-Estabrooks N, Stiassny-Eder D, Albert ML. Severe non-fluency in aphasia: role of the medial subcallosal fasciculus plus other white matter pathways in recovery of spontaneous speech. *Brain* 1989;112:1-38.
- Nielsen JM. *Agnosia, apraxia, aphasia: their value in cerebral localization*. 2nd ed. New York: Hoeber, 1946:119-120.
- Palumbo CL, Naeser MA. Comparison of acute and subacute CT scans for usefulness in predicting recovery of spontaneous speech and/or auditory comprehension in aphasia patients [Dissertation]. Boston: Boston University School of Medicine (in preparation).
- Palumbo CL, Nicholas MA, Baker EH, Alexander MP, Frumkin NL, Naeser MA. CT scan lesion sites associated with good response to a nonverbal computer-assisted visual communication (C-ViC) for patients with severe aphasia. Poster presented at the Academy of Aphasia Meeting, Toronto, Canada, October 1992.
- Porch BE. *Porch index of communicative ability*. Palo Alto, CA: Consulting Psychologists Press, 1967.
- Ramsberger G, Helm-Estabrooks N. Visual action therapy for bucco-facial apraxia. In: *Clinical aphasiology conference proceedings*. San Diego: College Hill Press, 1988.
- Rao PR. The use of Amer-Ind code with aphasic adults. In: Chapey R, ed. *Language intervention strategies in adult aphasia*. Baltimore: Williams & Wilkins, 1986:360-7.
- Ross ED. Localization of the pyramidal tract in the internal capsule by whole brain dissection. *Neurology* 1980;30:59-64.
- Sarno MT, Levita E. Recovery in aphasia during the first year post stroke. *Stroke* 1979;10:663-70.
- Sarno MT, Levita E. Some observations on the nature of recovery in global aphasia after stroke. *Brain Lang* 1981;31:1-12.
- Schulz ML, Pandya D, Rosene D. The somatotopic arrangement of motor fibers in the periventricular white matter and internal capsule in the rhesus monkey [Dissertation]. Boston: Boston University School of Medicine and Graduate School, 1993.
- Selnes OA, Knopman DS, Niccum N, Rubens AB, Larsen DL. Computed tomographic scan correlates of auditory comprehension deficits in aphasia: a prospective study. *Ann Neurol* 1983;13:558-66.
- Selnes OA, Niccum N, Knopman DS, Rubens AB. Recovery of single word comprehension: CT scan correlates. *Brain Lang* 1984;21:72-4.
- Signoret J-L, Castaigne P, Lhermitte F, Abelanet R, Laval P. Rediscovery of Leborgne's brain: anatomical description with CT scan. *Brain Lang* 1984;22:303-19.
- Sipponen J. Visualization of brain infarction with nuclear magnetic resonance imaging. *Neuroradiology* 1984;26:387-91.
- Skelly M, Schinsky L, Smith R, Donaldson R, Griffin J. American Indian sign Amerind as a facilitator of verbalization for the oral-verbal apraxic. *J Speech Hearing Disord* 1974;39:445-56.
- Skelly M, Schinsky L, Smith R, Donaldson R, Griffin J. American Indian sign: gestural communication for the speechless. *Arch Phys Med Rehabil* 1975;56:156-60.
- Smith AM, Bourbonnais D, Blanchette G. Interaction between forced grasping and a learned precision grip after ablation of the supplementary motor area. *Brain Res* 1981;222:395-400.
- Sparks R, Holland AL. Method: melodic intonation therapy for aphasia. *J Speech Hearing Disord* 1976;41:287-97.
- Steele RD, Weinrich M, Wertz RT, Kleczewska MK, Carlson GS. Computer-based visual communication in aphasia. *Neuropsychologia* 1989;27:409-26.
- Vignolo LA. Lesions underlying defective performances on the token test: a CT scan study. In: Boller F, ed. *Auditory comprehension: clinical and experimental studies with the token test*. Orlando, FL: Academic Press, 1979:161-7.
- Weinrich M, Steele R, Carlson GS, Kleczewska M, Wertz RT, Baker EH. Processing of visual syntax in a globally aphasic patient. *Brain Lang* 1989a;36:391-405.
- Weinrich M, Steele R, Kleczewska M, Carlson GS, Baker EH, Wertz RT. Representation of "verb" in a computerized visual communication system. *Aphasiology* 1989b;3:501-12.
- Yakovlev PI, Locke S. Limbic nuclei of thalamus and connections of limbic cortex. III. Corticocortical connections of the anterior cingulate gyrus, the cingulum, and the subcallosal bundle in monkey. *Arch Neurol* 1961;5:364-400.