

CLINICAL RESEARCH

Laser Acupuncture in the Treatment of Paralysis in Stroke Patients: A CT Scan Lesion Site Study

Margaret A. Naeser,¹ Michael P. Alexander,^{1,2} Denise Stiassny-Eder,¹ Vicki Galler,³ Judith Hobbs,³ David Bachman,^{1,4} Linda Nobles Lannin³

1. Department of Neurology and Aphasia Research Center
Boston University School of Medicine and Boston VA Medical Center
2. Department of Behavioral Neurology, Braintree Hospital, Braintree, MA
3. Formerly, Rehabilitation Medicine Service, Boston VA Medical Center
4. Presently, Dept of Neurology, Medical University of South Carolina, Charleston, SC

Abstract: Seven stroke patients received 20, 40 or 60 low-energy laser acupuncture treatments beginning at 10 months to 6.5 years poststroke (n=6); or at one month poststroke (n=1). A 20 mW gallium-aluminum-arsenide infrared diode laser (780nm) was used directly on acupuncture points on the arm, leg, hand and/or face for 20 or 40 sec. per point. Five of the seven patients (71%) had improvement following laser treatments. The cases with arm/leg paralysis had improvement in knee flexion, knee extension and/or shoulder abduction; the cases with hand paresis had improvement in finger and hand strength. All patients with improvement had lesion on CT scan in <50% of the motor pathway areas (mild-moderate paralysis). Those with no improvement had lesion in >50% of the motor pathway areas (severe paralysis). These results are similar to our previous research in which needle acupuncture was used to treat paralysis in stroke patients.

IN 1985, the first author (M.A.N.) observed the use of low-energy HeNe laser stimulation (as opposed to needle stimulation) on acupuncture points to treat paralysis in stroke patients at the Hua Shan Hospital, Shanghai Medical University, China. The following protocol was used: A 10 mW HeNe red-beam laser was applied for 4 minutes per acupuncture point (2.4 joules per point). Six points were used per treatment session on the paralyzed arm/leg, e.g., LI-4 (Hegu), LI-11 (Quchi), TW-9 (Sidu), ST-31 (Biguan), ST-36 (Zusanli), and GB-39 (Xuanzhong). The patient was treated every other day (3 times per week) for four weeks.

There are no controlled studies on the use of laser acupuncture in the treatment of

Please address all correspondence and reprint requests directly to Dr. Margaret A. Naeser, VA Medical Center (116-B), 150 South Huntington Ave. Boston, MA 02130.

This research was supported by the Robert Wood Johnson Foundation Grant No. 09052; Barnsider Management Corporation, Hamilton, Massachusetts.

This paper was presented at the Meetings of the Deutsche Artzgesellschaft fur Akupunktur, Freudensstadt, Germany, September 12, 1989.

paralysis. The following is a brief summary of low-energy laser research related to this area: Many acupuncture points have decreased-resistance, relative to the surrounding tissue.¹ The application of low-energy HeNe laser to decreased resistance points on the skin overlying musculoskeletal trigger points increases the electrical resistance of these points.² A return to normal skin resistance may indicate the resolution of a pathological condition in pain patients.³ Low-energy HeNe laser (one mW; 632.8 nm) may affect serotonin metabolism. A large increase in urinary excretion of 5-hydroxyindoleacetic acid was observed after 10 HeNe laser treatments in chronic pain patients successfully treated with HeNe laser.⁴ Further research by Walker has shown that irradiation of the skin overlying the median nerve at the wrist with low-energy HeNe laser produces a somatosensory evoked potential which has a latency equal to that observed after electrical stimulation of the same nerve.^{5(p282)} Since the low-energy HeNe laser produces no detectable thermal change, the results imply that photochemical reactions alter neuronal activity. The mechanism by which transduction occurs is not known.

Recent reports have suggested that low-energy laser can be effective in decreasing inflammation and facilitating wound healing,^{6,7} and reducing clonus in spinal cord injury cases.^{5(p285)} The effect of low-energy laser on the cellular level has been reviewed by Basford.⁸ Studies using low-energy laser stimulation of acupuncture points (instead of needle stimulation) to treat various disorders in adults and children have been reported in China since the early 1980s.⁹ Laser acupuncture has been reported to be helpful in the treatment of paralysis in babies and children with cerebral palsy.¹⁰⁻¹²

We have conducted previous research with needle stimulation of acupuncture points in the treatment of paralysis in stroke patients.¹³⁻¹⁵ In these studies, we treated 31 stroke patients with paralysis, in which computerized tomographic (CT) scan lesion

site information was available. Results indicated that CT scan information was helpful in better understanding which stroke patients recovered increased voluntary range of motion following needle acupuncture treatments. For example, all stroke cases who had a lesion on brain CT scan in less than 50% of the motor pathway areas (mild-moderate paralysis) had a beneficial effect following 20-40 acupuncture treatments over a 2-3 month period (n=18). However, almost all stroke cases (12/13) with a lesion on brain CT scan in greater than 50% of the motor pathway areas (severe paralysis) had no increase in voluntary range of motion following 20-40 acupuncture treatments. Overall, 18/31 cases (58%) had a beneficial effect. The acupuncture treatments were beneficial even in some cases treated as late as 2-8 years poststroke.

The purpose of the present study was two-fold: 1) to investigate the effectiveness of low-energy laser acupuncture in the treatment of paralysis in stroke patients; and 2) to investigate the relationship between a neuroanatomical lesion site on CT scan and the potential for improvement following laser acupuncture treatments. This is the first study to examine these relationships.

Materials and Method

Subjects

Seven stroke patients participated in the study, ranging in age from 48 to 71 years of age when entering the study (5 men and 2 women). Five cases had a single left hemisphere stroke; two cases had a single right hemisphere stroke. Five patients were treated for residual arm/leg paralysis. These patients had greatly reduced arm and leg power (and severely reduced or no voluntary isolated finger movement). See Table 1. The two remaining cases were treated for hand paresis only (cases C.T. and P.R., ages 71 and 68). These patients had good arm and leg power, but they had mildly reduced isolated finger movement. CT scans were obtained on all patients after at least 3 months poststroke.

Six patients began receiving the laser acupuncture treatments during the chronic phase poststroke, ranging from 10 months to 6.5 years poststroke. These times are well beyond the spontaneous recovery period of up to 6 months poststroke.^{16,17} Because most patients were well beyond this period, each patient served as his/her own control; no sham laser treatments were administered. One patient (case P.R.), a hand palsy case, began receiving the laser acupuncture treatments during the acute phase, one month poststroke.

Five patients had received needle acupuncture treatments during a previous acupuncture study (cases C.P., S.H., M.R., M.J. and C.T.). These patients had improved on at least two tests during the needle acupuncture study, following 20 or 40 needle acupuncture treatments; however, full range of motion scores had not yet been obtained on all tests. The last needle acupuncture treatments were administered ranging from 3 months to 3 years prior to beginning the present low-energy laser study. For these five patients, this study examined whether *additional* improvement could be obtained with laser acupuncture treatments. One arm/leg patient (case F.J.) and one hand palsy patient (case P.R.) treated with laser acupuncture in the present study had not been part of the previous needle acupuncture study.

None of the stroke patients were receiving physical therapy or occupational therapy treatments during the course of the laser acupuncture treatments.

Laser Acupuncture Treatment Protocol

A 20 mW gallium-aluminum-arsenide (780 nm) infrared diode laser (Uni-laser, Denmark) was used for 20-40 seconds to irradiate each acupuncture point. With this Class III-b laser, 50 seconds of exposure is equivalent to one joule. The laser was applied for 20 seconds on shallow acupuncture points (hands and face) and for 40 seconds on deeper acupuncture points (arms and legs).

The following points were used on the paralyzed arm:

- LI-4 (Hegu)
- LI-11 (Quchi)
- LI-15 (Jiayu)
- TW-5 (Waiguan)
- TW-9 (Sidu) and
- Baxie points (located between the heads of the metacarpal bones)

Points used on the paralyzed leg:

- ST-31 (Biguan)
- ST-36 (Zusanli)
- GB-34 (Yanglingquan)
- GB-39 (Xuanzhong)
- LV-3 (Taichong)

Points used on the non-paralyzed side:

- LI-4 (Hegu)
- ST-36 (Zusanli)

These are the same acupuncture points which were treated in our previous study utilizing needle acupuncture for paralysis in stroke patients.¹³⁻¹⁵

If facial paralysis was present, the laser was applied for 20 seconds on the following acupuncture points on the paralyzed side:

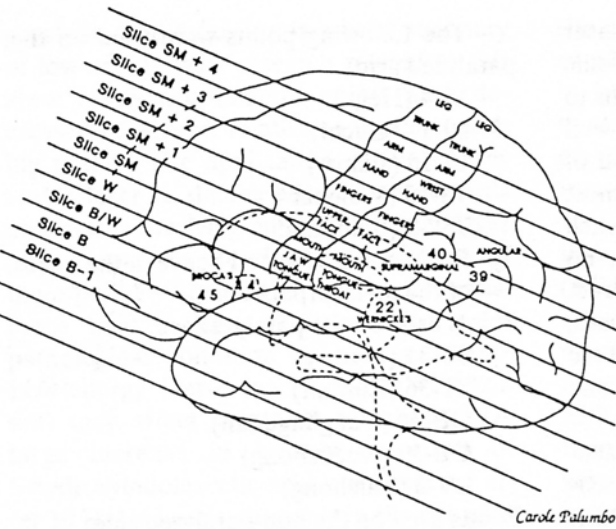
- ST-4 (Dicang)
- ST-6 (Jiache)
- ST-7 (Xiaguan)
- LI-20 (Yingxiang)
- SI-18 Quanliao)

These points were located according to anatomic criteria described by O'Connor and Bensky.¹⁸ Each laser treatment lasted approximately 30 minutes; subjects were treated 3 - 5 times per week as outpatients.

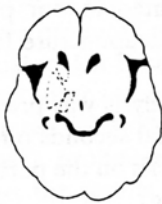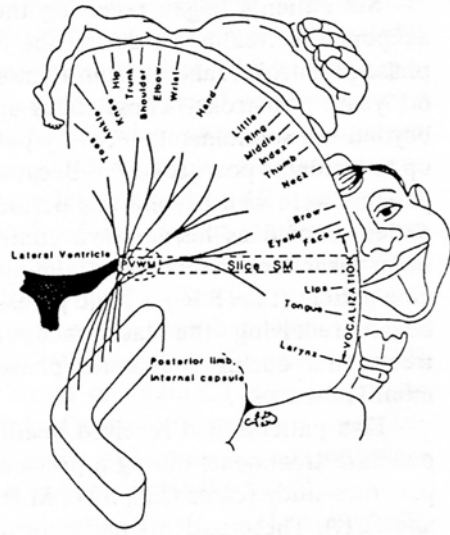
The 20 mW infrared laser which was used produces no sensation (neither heat nor pain) during its application to the skin. Institutional Review Board approval was obtained prior to use and informed consent was obtained from the patients.

Motor Evaluation

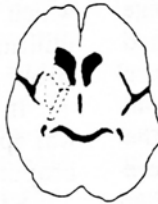Arm/Leg Tests: A motor examination, the Boston Motor Inventory,¹⁹ was designed for and used in all of our acupuncture research projects. This test measured the isolated active range of motion for four leg and three arm movements on the involved side,



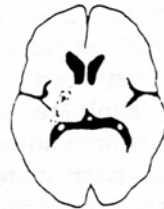Carole Palumbo



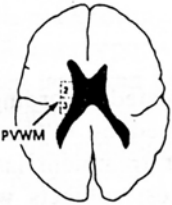
Slice B



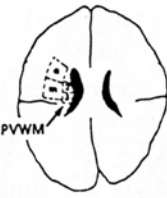
Slice B/W



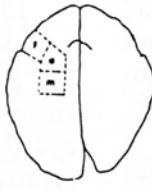
Slice W



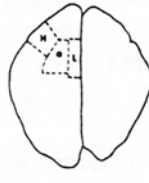Slice SM



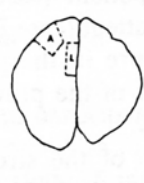Slice SM+1



Slice SM+2



Slice SM+3



Slice SM+4 or
Near Vertex Slice

Carole Palumbo

Figure 1.

Lateral, coronal and cross-sectional diagrams showing location of neuroanatomical areas visually assessed for extent of lesion (amount of infarction) on CT scan, containing, in part, descending pyramidal tract pathways for the leg, arm and hand. The deep, subcortical periventricular white matter (PVWM) area is outlined in the upper right coronal diagram and shown on CT scan slices SM+1 and SM in the lower portion of the diagram (arrows). The total extent of lesion in the 2nd and 3rd quarters (Qtrs.) of the PVWM area was related to improvement, versus no improvement, following the laser (or needle) acupuncture treatments. Key to abbreviations: L = leg cortex area; A = arm cortex area; H = hand cortex area; F = fingers cortex area; a = anterior white matter area; m = middle white matter area; 2 = 2nd Qtr. PVWM; 3 = 3rd Qtr. PVWM; PL = posterior limb of the internal capsule (continues on slices B/W and B). The head of the caudate and putamen were also assessed for extent of lesion. (The CT scan angle is 20 degrees to the cantho-meatal line.) (Reprinted with permission, *Journal of Neurologic Rehabilitation*, Demos Publications, NY, 1992.)

all proximal. These tests included hooklying abduction/adduction; knee flexion; knee extension; ankle dorsiflexion; shoulder abduction; forearm supination, elbow flexed; and forearm supination, elbow extended.

The evaluation was performed by one of three physical therapists who was blind as to the treatment type for all the acupuncture research projects. These research projects had included stroke patients receiving real needle acupuncture, sham needle acupuncture, no acupuncture or laser acupuncture. Thus, this study was double-blind for the therapists obtaining the pre-treatment (pre-Tx) and post-treatment (post-Tx) test data.

The patients were tested a few days prior to the first laser acupuncture treatment, and within a few days after completing the 20th, 40th and/or 60th laser acupuncture treatment. Some patients received only 20 or 40 laser treatments. The number of treatments a patient received (20, 40 or 60) was based solely on patient availability and transportation issues. All patients were offered a maximum of 60 laser treatments over a 3-4 month period.

Hand Tests: Hand strength testing was performed by an occupational therapist who was blind as to the treatment type, as described above for the physical therapists performing the arm/leg testing. The hand strength testing was performed on the two cases whose poststroke involvement included only the right (dominant) hand (cases C.T. and P.R.).

CT Scan Lesion Site Analysis

CT scans were performed after at least three months poststroke in all cases in order to better visualize the complete borders of the area of infarction.²⁰ The CT scans were analyzed retrospectively after the entire study had been completed. Figure 1 shows neuroanatomical diagrams for the hypothetical location of descending pyramidal tract pathways for the leg, arm and hand on CT scan. These diagrams were developed for this research project from previously published studies.²¹⁻²⁴

The extent of lesion (degree of damage) within each neuroanatomical area on CT scan was visually assessed for each patient (see Figure 1, lower portion). These areas contain, in part, descending pyramidal tract pathways for the leg, arm and hand. A 0-to-5 point scale was used, in which:

- 0 = no lesion
- 1 = equivocal lesion
- 2 = small, patchy or partial lesion
- 2.5 = patchy, <50% of area has lesion
- 3 = 50% of area has lesion
- 3.5 = patchy, >50% of area has lesion
- 4 = >50% of area has lesion
- 5 = total area has complete lesion.

Lesions were analyzed in a sequential manner from the cortical level to the sub-cortical levels including the white matter, the posterior limb of the internal capsule, and the brain stem level. An extensive lesion at an upper level rendered an additional lesion at the lower levels less important.

Our previous research with needle acupuncture in the treatment of paralysis in stroke patients had indicated that the periventricular white matter (PVWM) area at the level of the body of the lateral ventricle (CT scan slices SM+1 and SM), was an especially important area to examine in relationship to the potential for improvement following acupuncture. The location of the PVWM area on CT scan is diagrammed in Figure 1, lower portion (see arrows). Results from our research with needle acupuncture indicated that patients who had a lesion in <50% of the PVWM area had increased voluntary range of motion following a series of acupuncture treatments; patients who had lesion in >50% of the PVWM area, however, had no increase in voluntary range of motion. These patients with no improvement had severe paralysis and the PVWM lesion extended so deep that it was immediately adjacent to the body of the lateral ventricle.¹³⁻¹⁵

The total extent of lesion within the PVWM on CT scan for each patient with arm/leg paralysis in the present study is listed in Table 1-B.

Table 1.

Pre- & post-treatment test scores for stroke patients with arm/leg paralysis treated with laser acupuncture

A. LOWER EXTREMITY Test Scores

Cases w/ lesion:	Age enter study	Months post onset test times	% isolated active range of motion per Boston Motor Inventory (BMI)											
			Hooklying abd./add.			Knee flexion			Knee extension			Ankle dorsiflexion		
			Pre Tx.	Post 20	Post 40	Pre Tx.	Post 20	Post 40	Pre Tx.	Post 20	Post 40	Pre Tx.	Post 20	Post 40
<50% m.p.*														
CP	54	10/12/13	100	100	100	19	30	35	88	88	100	0	8	-
SH	65	5/12/13	100	100	100	46	46	54	77	77	89	54	54	55
MR ^a	51	24/25	100	100	-	0	0	-	33	44	-	9	9	-
>50% m.p.*														
MJ	58	77/78/80	100	100	100	30	33	30	78	67	66	0	5	5
FJ ^a	48	48/50	100	100	-	0	0	-	0	0	-	0	0	-

B. UPPER EXTREMITY Test Scores: Total lesion extent in PVWM and total No. of improved tests

Cases w/ lesion:	% isolated active range of motion per BMI									Total lesion extent** in PVWM (slices: SM+1 and SM)	Total no. tests improved by ≥ 10% Post	
	Shoulder abduction			Forearm supin. elbow flexed			Forearm supin. elbow extended				20 or 40 Tx.	
	Pre Tx.	Post 20	Post 40	Pre Tx.	Post 20	Post 40	Pre Tx.	Post 20	Post 40			
<50% m.p.*												
CP	72	72	100	0	0	0	0	0	0	0 ^b	-	3
SH	0	0	0	0	0	0	0	0	0	9.0	-	1
MR ^a	50	55	-	0	0	0	0	0	-	3.0	-	1
>50% m.p.*												
MJ	100	100	100	27	27	0	0	0	0	14.4	-	0
FJ ^a	0	0	-	0	0	-	0	0	-	20.0	-	0

* Motor pathway;

** 20 = complete lesion; 10 = half lesion

a. Patient had right hemisphere lesion, and left-sided paralysis; all other patients had left hemisphere lesion and right-sided paralysis.

b. Cerebral peduncle

Table 2.

Pre- & post-treatment test scores for two stroke patients with hand paresis treated with laser acupuncture

Case	Age enter study	Months post onset test times	No. of laser acupun. Tx.s	Grip strength ^a (in lbs)		3-Jaw chuck ^b (in lbs)		Tip pinch ^c (in lbs)		Lateral pinch ^d (in lbs)	
				Pre	Post	Pre	Post	Pre	Post	Pre	Post
CT	71	33 / 34	20	62.7	68.4	12	18.0	8	11.0	12.0	14.0
PR	68	1 / 4	20	32.2	47.7	0	11.3	0	10.7	3.7	14.7

a. Hand strength test

b. Finger strength test: the strength in the first two fingers opposing the thumb

c. Finger strength test: the strength in the index finger opposing the thumb

d. Finger strength test: the strength in the thumb opposing the lateral surface of the index finger

The following method was used to rate the PVWM area. The PVWM area contains four quarters at CT scan slice SM+1 and four quarters at CT scan slice SM. Only the second and third quarters appear to be relevant for motor pathway areas at each slice. Therefore, the extent-of-lesion ratings (0-5) were computed for the second and third quarters of the PVWM area at slice SM+1, and the second and third quarters of the PVWM at slice SM (e.g., a total of four quarters over two slices). Each quarter has a maximum extent-of-lesion rating of 5. Thus, a total lesion of 10 equals a maximum lesion rating (5) in two of the quarters (or *half* of the total PVWM areas rated). A total extent-of-lesion rating of 20 equals a maximum lesion rating (5) in all four of the quarters (or complete, total lesion in the PVWM areas rated).

After the study was completed, the lesion site data were used to classify each patient as having a lesion in either <50% of the motor pathway areas (e.g., total lesion extent value of <10 for the PVWM area), or >50% of the motor pathway areas (e.g., total lesion extent value of >10 for the PVWM area).

Results

For patients treated for arm/leg paralysis, improvement was defined as an increase of at least 10 percent isolated active range of motion on at least one of the seven arm/leg tests following 20, 40 or 60 laser acupuncture treatments. For the patients treated for hand paresis, improvement was defined as an increase of at least one pound (lb: 16 ounces or 2.2 kilograms) on at least one hand strength test, following 20, 40 or 60 laser acupuncture treatments. Overall, five of the seven stroke patients (71.4%) treated with laser acupuncture showed improvement. Four of the six chronic stroke patients (66.7%) showed improvement. The single acute stroke patient who was treated with laser acupuncture also showed improvement (patient P.R., the hand paresis case).

Cases with Arm/Leg Paralysis

The pre-Tx and post-Tx test scores for the five patients with arm/leg paralysis who were treated with laser acupuncture are presented in Table 1. This table shows that there was improvement for three of these five arm/leg cases treated with laser acupuncture (cases C.P., S.H. and M.R.). All three of these arm/leg cases with improvement showed an increase of at least 10% isolated active range of motion on knee extension; one case showed improvement on knee flexion (case C.P.); and one case, on shoulder abduction (case C.P.).

Cases with Hand Paresis

The two cases with hand paresis showed improvement in hand strength. For case C.T., before the laser acupuncture treatments were initiated at 2 years 9 months poststroke, the right-hand grip strength was 62.7 lbs; at 34 months poststroke following 20 laser acupuncture treatments, it was 68.4 lbs. When this patient had first entered the *needle* acupuncture study at 2 months poststroke, the grip strength was only 26.4 lbs. After 20, 40 and 60 needle acupuncture treatments, it had increased to 44, 53 and 62 lbs, respectively. See Table 2 for additional finger strength test results for case C.T.

For case P.R., the 20 laser acupuncture treatments were initiated at one month poststroke. See Table 2 for grip strength and finger strength test results.

CT Scan Lesion Site Analysis

The five cases who showed improvement following the laser acupuncture treatments (three arm/leg cases, C.P., S.H. and M.R.; and two hand cases, C.T. and P.R.) had either no lesion or lesion which was present in <50% of the motor pathway areas, including the PVWM area on CT scan slices SM+1 and SM. For the three arm/leg cases (C.P., S.H. and M.R.), see Table 1-B, last two columns. The two hand cases (cases C.P. and P.R.) each had no lesion in the PVWM area on CT scan slices SM+1 and SM. They had small white matter lesions which

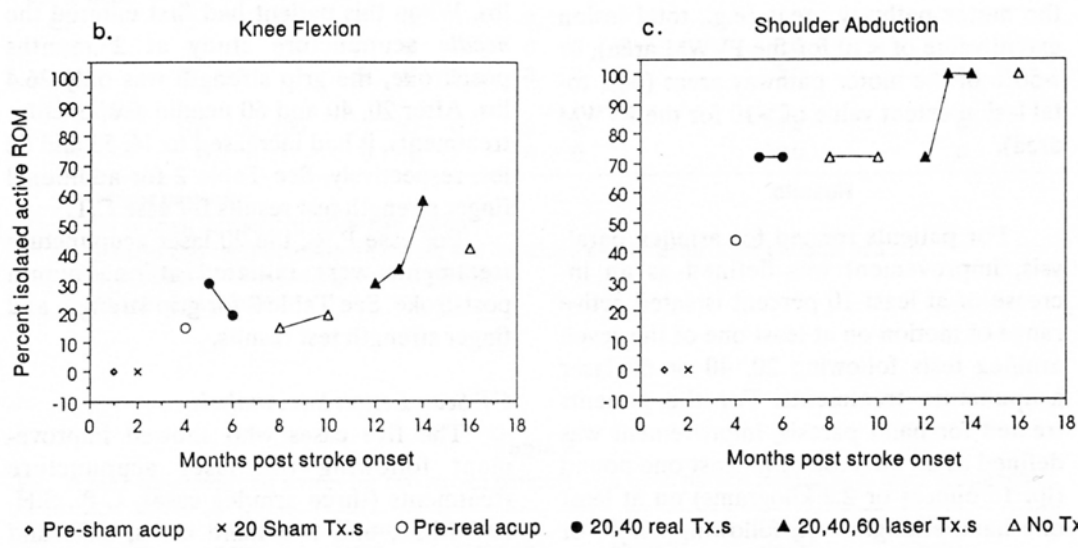
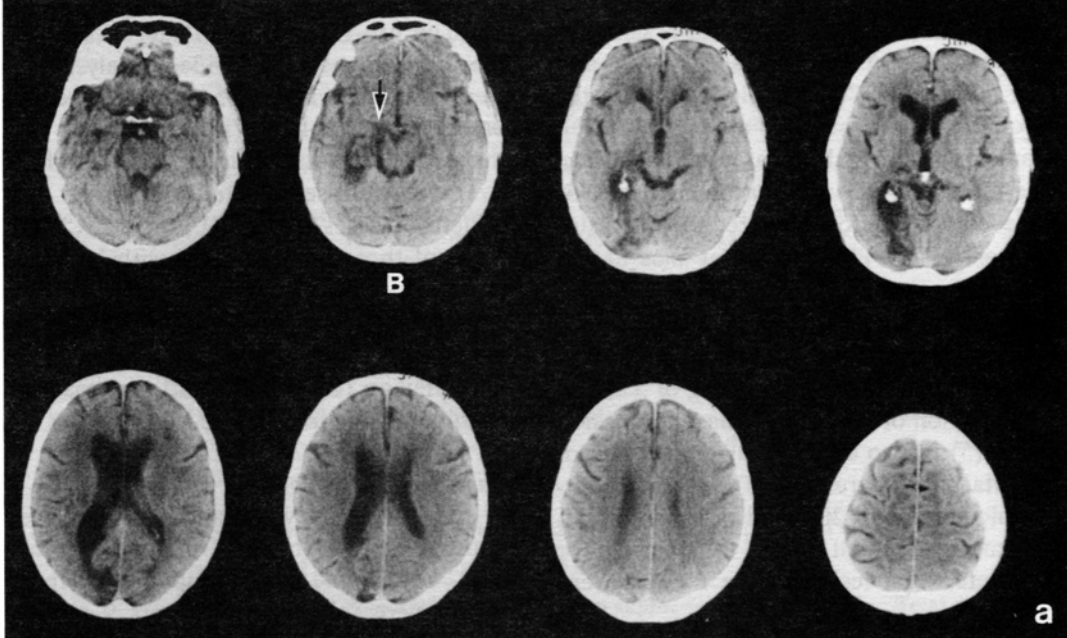


Figure 2.

(a) CT scan obtained 7 months poststroke for case C.P., a 54-year-old man. (The left hemisphere lesion is shown on the left side of the CT scan.) The paralysis is not associated with lesion in either the cortex or the subcortical PVWM area; it is associated with lesion in the cerebral peduncle (arrow, slice B).

(b and c) Case C.P. had improvement following 20, 40, and 60 laser acupuncture treatments beginning after 10 months poststroke. His knee flexion increased from 19% pre-laser, to 30, 35 and 58% following 20, 40 and 60 laser acupuncture treatments. Although the score for knee flexion was slightly decreased at 2 months post the last laser treatment (see b), the improvement in shoulder abduction remained stable following the last laser treatment (see c).

were deep to the motor cortex area for hand.

The two arm/leg cases who showed no improvement (cases M.J. and F.J.) each had lesion in >50% of the motor pathway areas, including the PVWM area. See Table 1-B, last two columns.

Case Examples

The CT scans and pre-Tx and post-Tx test scores for two arm/leg cases who had improvement following the laser acupuncture treatments are provided in Figures 2 and 3 (cases C.P. and S.H.).

Two CT scans, and pre-Tx and post-Tx test scores for an arm/leg case who had no improvement following the laser acupuncture treatments are provided in Figure 4 (case M.J.). Although case M.J. had experienced improvement following the needle acupuncture treatments which had been initiated at 3 years poststroke, he had no improvement following the laser acupuncture treatments which were initiated at 6 years poststroke. The first CT scan for case M.J., performed at 3 years poststroke, had shown only minimal lesion in the PVWM area, and lesion was present in <50% of the motor pathway areas, i.e., a lesion pattern which was compatible with improvement following acupuncture treatments (see Figure 4a).

A second CT scan was then performed at 6 years poststroke for case M.J., after the finding of no improvement following the laser acupuncture treatments (see Figure 4b). This CT scan revealed extensive lesion expansion into the PVWM area. Lesion was now present in >50% of the PVWM area, and located immediately adjacent to the body of the lateral ventricle on CT scan slice SM+1. There was no documented event for a second stroke, however, his wife observed slowness about 6 months before the laser treatments were begun. Thus, it is hypothesized that the finding of no improvement following laser acupuncture treatments in this case was related to expansion of the lesion into the PVWM area, an area which

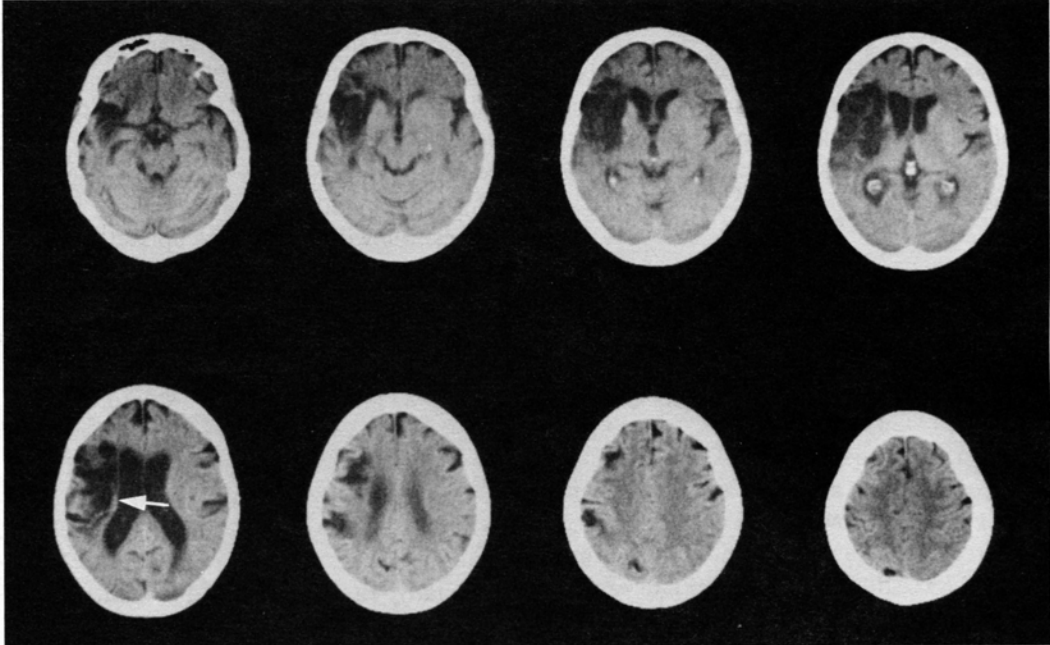
appears to be important regarding the potential for improvement following needle or laser acupuncture treatments.

The CT scan for a patient with right hemisphere stroke and severe left-sided hemiplegia is shown in Figure 5 (case F.J.). This patient had no improvement in arm/leg scores following 20 laser acupuncture treatments. Lesion was present in >50% of the motor pathway areas, including the PVWM area. However, this patient did have improvement in her left facial paralysis following the 20 laser acupuncture treatments, i.e., the left side of her face lifted and became more symmetric with the right. She also regained the ability to control food and liquids in the left side of her mouth for the first time in 4 years following stroke onset. Additionally, she reported a loosening of the left Achilles tendon which helped to improve walking.

Discussion

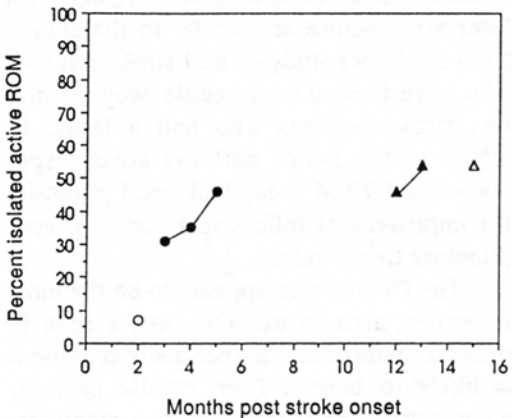
The results from this small study with seven stroke patients who were treated with laser acupuncture are similar to the results from our larger study with 31 stroke patients who were treated with needle acupuncture, i.e., stroke patients who had a lesion in <50% of the motor pathway areas (especially the PVWM area) had good potential for improvement following a series of acupuncture treatments.

The PVWM area appears to be the most important area to examine on CT scan in order to determine whether a stroke patient is likely to benefit from needle or laser acupuncture. This area contains many important intra- and inter-hemispheric pathways including, in part, the following: 1) the descending pyramidal fibers from the motor cortex, where the pathways for the leg are most medial,²⁵ 2) the body of the caudate nucleus, 3) the mid-callosal pathways, 4) the medial subcallosal fasciculus containing connections to the caudate from the supplementary motor area and the cingulate gyrus,²⁶⁻²⁸ 5) the occipito-frontal fasciculus,²⁷ and 6) the superior lateral thalamic pedun-

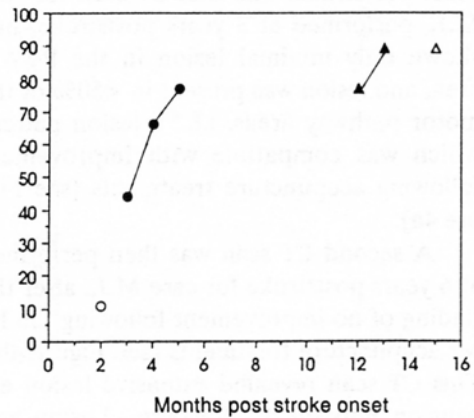


a.

b. Knee Flexion



c. Knee Extension



○ Pre-acupun ● 20,40,60 acupun. Tx.s ▲ 20,40 laser Tx.s △ No Tx.

Figure 3.

(a) CT scan obtained at 5 months poststroke for case S.H., a 65-year-old woman. The CT scan shows sparing of only the deepest PVWM pathways on slice SM (arrow), i.e., sparing of some leg fibers. The arm fibers are more lateral and anterior, where extensive lesion was present. The arm paralysis was severe with scores of 0% on all arm testing throughout the study.

(b and c) This patient showed improvement only in leg testing. Her knee extension increased from 77% to 89%, following 40 laser treatments. Her husband reported that following the laser treatments, for the first time since her stroke (13 months earlier), she was able to climb up and down stairs. These improved scores remained stable at 2 months post the last laser treatment (15 months poststroke).

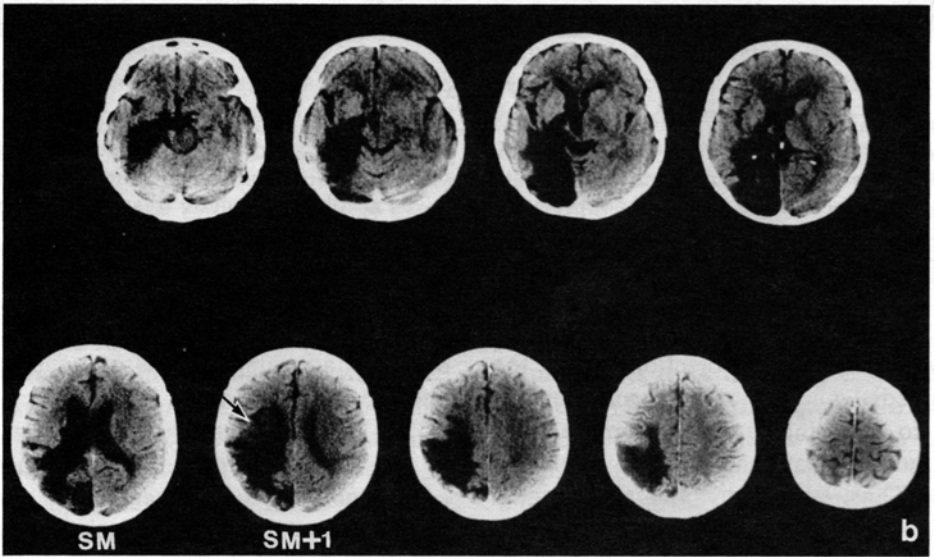
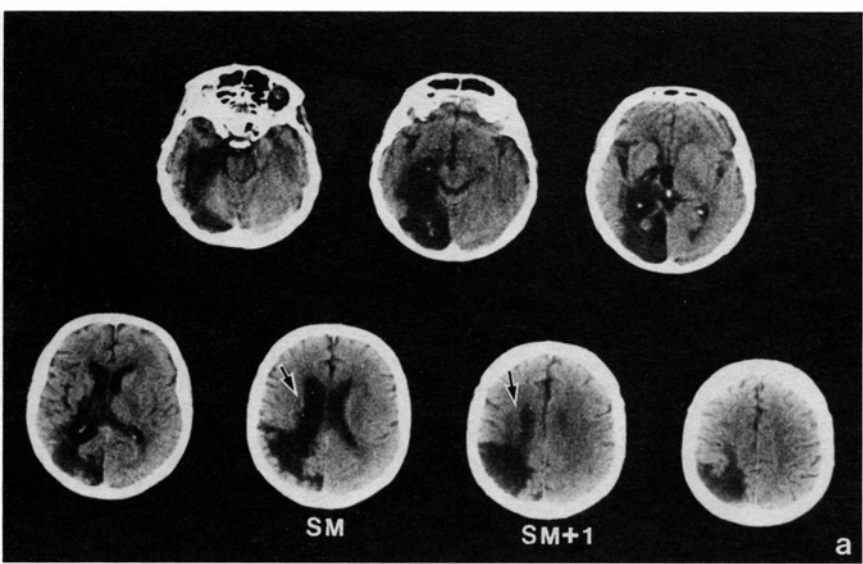


Figure 4.

(a) Two CT scans for case M.J. Case M.J. first entered the needle acupuncture study at 3 years poststroke and had improvement, but he had no improvement with the laser acupuncture treatments following new "lesion expansion" 3 years later (6 years poststroke). The CT scan in (a) was performed 3 years poststroke, and shows relative sparing of the PVWM area at slices SM+1 and SM (arrows). At this time, his paralysis was primarily associated with lesion in the posterior limb of the internal capsule and he had improvement following 20 and 40 needle acupuncture treatments in which he improved in shoulder abduction, knee flexion, knee extension and supinate forearm, elbow flexed.

(b) This CT scan was performed at 6 years poststroke. Sometime between 3 and 6 years post the first stroke, there was extensive "lesion expansion" into the PVWM area (arrow). There was now no improvement following the laser acupuncture treatments which were administered at 6 years post the original stroke onset. (See c).

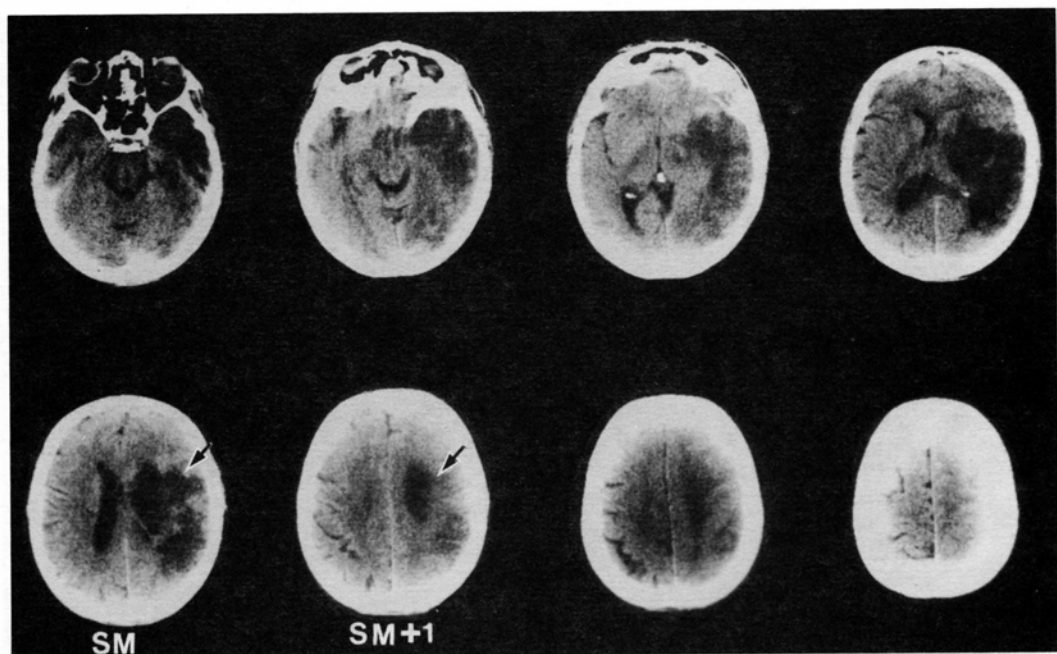


Figure 5.

CT scan obtained at 4 years poststroke for case F.J., 48-year-old woman. (The right hemisphere lesion is shown on the right side of the CT scan.) Lesion is present in the entire PVWM area on slices SM+1 and SM (arrows). She had no improvement following 20 laser acupuncture treatments which were begun at 4 years poststroke. (She had not previously received needle acupuncture treatments.) The laser acupuncture treatments did, however, loosen her left Achilles tendon and she was able to walk more comfortably. She also had improvement in the left central facial weakness following the laser treatments and had reduced problems with eating, e.g., food no longer pocketed inside her left cheek.

cle which includes projections from the dorsomedial nucleus and the anterior nucleus to the cingulate,²⁹ and projections from the ventrolateral nucleus to the motor cortex. Thus, even within this small region there are numerous motor systems that might, if incompletely damaged, respond to needle or laser acupuncture. These systems include dorsal striatum, supplementary motor area, or the frontal-striatal-ventrolateral thalamic-frontal loop, as well as the descending pyramidal system.

Although two patients in the present study had no improvement in arm/leg tests following the laser acupuncture treatments, one of these patients did have improvement in facial paralysis, control of food and liquids in the left side of her mouth, and a loosening of her left Achilles tendon.

The advantages of laser acupuncture include the following:

- 1) The laser is totally non-invasive,
- 2) The laser produces no sensation, neither pain nor heat,
- 3) Although Jing-Well points were not used in the present study, they can be stimulated painlessly, with low-energy laser.

Author M.A.N. has recently observed that stimulation of the Jing-Well points on the fingers (LU-11, Shaoshang; LI-1, Shangyang; PC-9, Zhongchong; TW-1, Guan-chong; HT-9, Shaochong; and SI-1, Shaoze), in combination with the use of a microamps TENS device (Microstim, Fort Lauderdale, Florida) placed on the hand (HT-8, Shaofu; and TW-5, Waiguan), is especially effective in treating hand paresis and spasticity in

stroke patients. Each Jing-Well point is treated for 3 minutes with a 5 mW, 670 nm red-beam, laser lecture pointer. This method is also helpful in the prevention of permanent contractures of the hand in patients with more severe hand paralysis.³⁰ The use of low-energy laser for long-term treatment is especially desirable for stroke patients with a chronic paralysis. In fact, the patient can be trained to treat himself at home using this inexpensive laser pointer and the TENS device described above.³⁰

None of the patients treated with laser acupuncture in the present study were receiving physical therapy (PT) or occupational therapy (OT) during the course of the study. Future studies may show, however, that a combination of needle and laser acupuncture, with standard PT or OT techniques may increase the potential for maximal functional gains.

Several acupuncture studies which have used needle acupuncture have observed that the best outcome levels were observed when acupuncture treatments were initiated at less than 3 months poststroke,³¹ and especially when the acupuncture treatments were initiated less than 24 hours and 36 hours poststroke.^{32,33} In acute cerebral hemorrhage cases, the acupuncture is initiated after the acute bleeding has stopped.³² However, in our previous needle acupuncture research with chronic stroke patients, we have observed improvement following 20 or 40 acupuncture treatments which were initiated even as late as 8 years poststroke in patients whose CT scan lesion sites revealed damage in <50% of the motor pathway areas.^{14,15}

A recent study from Sweden has observed a positive response following needle acupuncture treatments in stroke patients.³⁴ There was significantly more improvement in walking, balance, activities of daily living, quality of life, mobility and emotion in a group of stroke patients treated with needle acupuncture beginning at 4 - 10 days post-stroke (for 10 weeks), versus a group of stroke patients not treated with acupunc-

ture. The average cost of medical care for the acupuncture treated group was an equivalent of \$26,000 less per patient, due to less time required in rehabilitation and nursing home facilities. Future studies in the U.S. on the cost-effectiveness of stroke patients treated with needle and/or laser acupuncture would seem appropriate.

The mechanism underlying the effect of laser acupuncture on the treatment of paralysis in stroke patients is not understood at this time. Research from China has suggested that needle acupuncture on the scalp increases cerebral blood flow in stroke patients.³⁵ There are two other studies which support this notion. Omura stimulated acupoint ST-36 (Zusanli) on the left (paralyzed) leg in stroke patients and observed an increase in cerebral blood flow to the right supraorbital artery (representing right cerebral hemisphere blood flow), ipsilateral to the hemisphere where the stroke had occurred.³⁶ An increase in blood circulation to the left (paralyzed) hand (and right hand) of the patients was also observed. Chen and Erdmann stimulated an acupuncture point on the midline face, above the upper lip (GV-26, Renzhong), in rats and observed an increase in tissue oxygenation to the frontal cortex areas, bilaterally.³⁷ Thus, results from these three studies suggest that insertion of acupuncture needles into different acupuncture points on the scalp, leg or face may all increase cerebral blood flow and circulation. It is possible that this increase in cerebral blood flow and circulation is one mechanism that is involved with mediating the slow improvement of paralysis in stroke patients.

Some physiological mechanisms involved with brain tissue damage and infarction have been examined with regional cerebral blood flow studies (rCBF).³⁸ There is a gradual decrease in rCBF from the peri-infarct area into the center of the infarct and there is a significant correlation between reduced blood flow and neuronal loss in the cortex.³⁹ If some silent neurons are still viable in the peri-infarct areas, even

in chronic cases, the increase in blood flow may be affecting these neurons in some manner. In addition, the acupuncture treatments may be increasing collateral blood flow in some way, and this may also be affecting silent areas or possibly creating alternative neuronal connections.

The notion that increased rCBF in additional neuroanatomical areas may be involved with recovery of paralysis in stroke patients has been recently studied with positron emission tomography (PET).⁴⁰⁻⁴² These studies have observed increase in rCBF, for example, in neuroanatomical areas contralateral to the side of the brain lesion, and ipsilateral to the paralyzed side.

Additional research with low-energy laser and/or needle stimulation in the treatment of paralysis due to stroke appears warranted. These studies would be especially valuable if conducted in combination with rCBF monitoring.

Acknowledgment

The authors would like to gratefully acknowledge the following acupuncturists who provided the laser acupuncture treatments for this study: Barry Levine, LicAc, Carlos Ochoa-Valdivieso, MD, and Richard Wallace, LicAc, RD; and Chunhan Zhu, OMD, who served as Traditional Chinese Medicine consultant. We also thank Daniel F. Bensky, OMD, DO, Andrew Gamble, OMD, Ted Kaptchuk, OMD, Margaret Caudill, MD, Shirley Stockmeyer, RPT and Ellie Hendrie and Bruce Grassfield for early consultations and assistance. We also thank Helen Moffett, RPT, Lourdes Lopez-Visconti, OTR, Jo Wright, OTR, Linnea Carlson, MS and Ann Gaddie, MS for additional testing; Errol Baker, PhD for statistical consultation and Carole Palumbo and Malee N. Prete for CT scan assistance. We also gratefully acknowledge the generous exchange of acupuncture information from the Hua Shan Hospital, Institute of Neurology, Shanghai Medical University, including Xiubing Wei, MD, Gongbai Chen, MD, Weixian Zhang, MD, Shengchang Li, MD, Qimei Zhang, OMD, Yaochen Hou, OMD, Youan Fang, OMD, Jingli Yao MD, Zhenbang Xu, MD, and Eric Chen.

About the Author

Margaret Naeser has a BA from Smith College, and a PhD in Linguistics, from the University of Wisconsin. She is Director of the CT/MRI Scan Brain Imaging Aphasia Research Laboratory at the Boston University Aphasia Research Center at the Boston Veterans Affairs Medical Center and Associate Research Professor of Neurology, Boston University School of Medicine. A graduate of the

New England School of Acupuncture, Watertown, MA, she is a licensed acupuncturist in Massachusetts. She has conducted research with acupuncture in the treatment of paralysis in stroke patients at the Boston VA Medical Center, and is currently conducting research there with laser acupuncture in the treatment of carpal tunnel syndrome. Author of over 50 articles on brain imaging and aphasia and three articles on acupuncture in the treatment of paralysis in stroke, she has published two books: *Outline Guide to Chinese Herbal Patent Medicines in Pill Form—with Sample Pictures of the Boxes* and *Laser Acupuncture, An Introductory Textbook for the Treatment of Pain, Paralysis, Spasticity and Other Disorders* (Boston Chinese Medicine, Boston, MA).

References

1. Hyvarinen J, Karlsson M: Low-resistance skin points that may coincide with acupuncture loci. *Med. Biol* 1977; 55: 88-94.
2. Snyder-Mackler L, Bork C, Bourbon B, et al: Effect of helium-neon laser on musculoskeletal trigger points. *Physical Therapy*, 1986; 66(7): 1087-1090.
3. Riley LH, Richter CP: Use of the electrical skin resistance method in the study of patients with neck and upper extremity pain. *Johns Hopkins Med J*, 1975; 137: 69-74.
4. Walker JB: Relief from chronic pain by low power laser irradiation. *Neuroscience Letters*, 1983; 43: 339-344.
5. Walker JB, Akhanjee LK: Laser-induced somatosensory evoked potentials: Evidence of photosensitivity in peripheral nerves. *Brain Research*, 1985; 344(2): 282, 285.
6. Seitz LM, Kleinkort JA: Low-power laser: Its application in physical therapy, in Michlovitz SL, Wolf SL (eds.): *Thermal Agents in Rehabilitation*. F.A. Davis Company, Philadelphia, 1986: pp 217-238.
7. Mester E, Mester AF, Mester A: The biomedical effects of laser application. *Lasers in Surgery and Medicine*, 1985; 5: 31-39.
8. Basford JR: Low-energy laser therapy: Controversies and new research findings. *Lasers in Surgery and Medicine*, 1989; 9: 1-5.
9. *Second National Symposium on Acupuncture and Moxibustion and Acupuncture Anesthesia*. All-China Society of Acupuncture and Moxibustion, Beijing, China, August 7-10, 1984, pp 140-149, 545-546.
10. Filipowicz WA: The application of modern acupuncture techniques and methods on children with cerebral palsy. *Amer J Acupun*, 1991; 19(1): 5-9.
11. Lidicka M: Results of acupuncture and laser acupuncture in the treatment of paralysis in brain-damaged babies and children in hospitals in Prague, Czech Republic. Paper presented at International Council for Medical Acupunc-

- ture and Related Techniques (ICMART) Meetings, Munich, Germany, June 16, 1991.
12. Hegyi G: Clinical use of acupuncture and laser acupuncture with brain-damaged babies and children, and adults with multiple sclerosis in hospitals in Budapest, Hungary. Paper presented at meetings of the International Council for Medical Acupuncture & Related Techniques (ICMART), Munich, Germany, June 16, 1991.
 13. Naeser MA, Alexander MP, Stiassny-Eder D, et al: Real versus sham acupuncture in the treatment of paralysis in acute stroke patients: A CT scan lesion site study. *J Neurologic Rehabilitation*, 1992; 6: 163-173.
 14. Naeser MA, Alexander MP, Stiassny-Eder D, et al: Acupuncture in the treatment of hand paresis in chronic and acute stroke patients: Improvement observed in all cases. *Clinical Rehabilitation*, 1994; 8: 127-141.
 15. Naeser MA, Alexander MP, Stiassny-Eder D, et al: Acupuncture in the treatment of paralysis in chronic and acute stroke patients: Improvement correlated with specific CT scan lesion sites. *Acupun Elec*, 1994; 19(4): 227-249.
 16. Bard G, Hirschberg GG: Recovery of voluntary motion in upper extremity following hemiplegia. *Arch Phys Med Rehabil*, 1965; 46: 567-572.
 17. Sunderland A, Tinson D, Bradley L, et al: Arm function after stroke: An evaluation of grip strength as a measure of recovery and a prognostic indicator. *J Neurol Neurosurg Psych*, 1989; 52: 1267-1272.
 18. O'Connor J, Bensky D (trans/eds): *Acupuncture: A Comprehensive Text*. Translated from the Shanghai College of Traditional Medicine. Eastland Press, Chicago, 1981.
 19. Galler V, Hobbs J: Boston Motor Inventory Test. Presented at the National Stroke Rehabilitation Conference, sponsored by Spaulding Rehabilitation Hospital, Cambridge, Massachusetts, April 29, 1988. Originally printed through Physical Therapy Svc., V.A. Medical Center, Boston, MA 02130. Now available through J. Hobbs, Physical Therapy Svc., V.A. Medical Center, White River Junction, VT.
 20. Palumbo CL, Naeser MA: Comparison of acute and subacute CT scans for usefulness in predicting recovery of spontaneous speech and/or auditory comprehension in aphasia patients. Presented at aphasia grand rounds, Boston VA Medical Center, Jan 5, 1995.
 21. Mizukami M, Nishijima M, Kin H: Computed tomographic findings of good prognosis for hemiplegia in hypertensive putaminal hemorrhage. *Stroke*, 1981; 12(5): 648-652.
 22. Knopman DS, Rubens AB: The validity of computed tomographic scan findings for the localization of cerebral functions: The relationship between computed tomography and hemiparesis. *Arch Neurol*, 1986; 43: 328-332.
 23. Ross ED: Localization of the pyramidal tract in the internal capsule by whole brain dissection. *Neurol*, 1980; 30: 59-64.
 24. Naeser MA, Palumbo CL, Helm-Estabrooks N, et al: Severe non-fluency in aphasia: Role of the medial subcallosal fasciculus and other white matter pathways in recovery of spontaneous speech. *Brain*, 1989; 112: 1-38.
 25. Schulz ML, Pandya D, Rosene D: The somatotopic arrangement of motor fibers in the periventricular white matter and internal capsule in the rhesus monkey. PhD dissertation, Department of Behavioral Neuroscience, Boston University School of Medicine and Graduate School, 1993.
 26. Muratoff W: Sekundäre Degenerationen nach Durchschneidung des Balkens. *Neurologisches Centralblatt*, 1893; 12: 714-729.
 27. Dejerine J: *Anatomie des Centres Nerveux*. Rueff, Paris, 1895, pp 388-391.
 28. Yakovlev PI, Locke S: Limbic nuclei of thalamus and connections of limbic cortex. *Arch Neurol*, 1961; 5: 364-400.
 29. Mufson EJ, Pandya DN: Some observations on the course and composition of the cingulum bundle in the rhesus monkey. *J Comp Neurol*, 1984; 225: 31-43.
 30. Naeser MA, Wei XB: *Laser Acupuncture: An Introductory Textbook for Treatment of Pain, Paralysis, Spasticity and Other Disorders*. Boston Chinese Medicine, Boston, 1994, p 40.
 31. Zhang WX, Li SC, Chen GB, et al: Acupuncture treatment of apoplectic hemiplegia. *J Trad Chin Med*, 1987; 7(3): 157-160.
 32. Li DM, Li WD, Wei LH, et al: Clinical observation on acupuncture therapy for cerebral hemorrhage. *J Trad Chinese Med*, 1989; 9(1): 9-13.
 33. Hu HH, Chung C, Liu TJ, et al: A randomized controlled trial on the treatment for acute partial ischemic stroke with acupuncture. *Neuroepidemiology*, 1993; 12: 106-113.
 34. Johansson K, Lindgren I, Widner H, et al: Can sensory stimulation improve the functional outcome in stroke patients? *Neurol*, 1993; 43: 2189-2192.
 35. Academy of Traditional Chinese Medicine, Departments of Neurology and Physiology: Treatment of cerebral thrombosis by acupuncture and observation of 209 cases of convalescents and the effects of rheoencephalography and electromyogram. *National Symposium of Acupuncture*, Beijing, June 1979. Abstracted, *Advances in Acupuncture and Acupuncture Anesthesia*. The People's Medical Publishing House, Beijing, China, 1980, pp 69-70.
 36. Omura Y: Pathophysiology of acupuncture treatment: Effects of acupuncture on cardiovascular and nervous systems. *Acupun Elec*, 1975; 1: 51-141.

37. Chen GS, Erdmann W: Effects of acupuncture on tissue-oxygenation of the rat brain. *Comparative Medicine East and West*, 1977; 5(2): 147-154.
38. Symon L, Crockard HA, Dorsch NWC, et al: Local cerebral blood flow and vascular reactivity in a chronic stable stroke in baboons. *Stroke*, 1975; 6: 482-492.
39. Mies G, Auer LM, Ebhardt G, et al: Flow and neuronal density in tissue surrounding chronic infarction. *Stroke*, 1983; 14(1): 22-27.
40. Chollet F, DiPiero V, Wise RJS, et al: The functional anatomy of motor recovery after stroke in humans: A study with positron emission tomography. *Ann Neurol*, 1991; 29(1): 63-71.
41. Weiller C, Chollet F, Friston KJ, et al: Functional reorganization of the brain in recovery from striatocapsular infarction in man. *Ann Neurol*, 1992; 31: 463-472.
42. Weder B, Knorr U, Herzog H, et al: Tactile exploration of shape after subcortical ischaemic infarction studied with PET. *Brain*, 1994; 117, 593-605.