

# The effects of normal aging on myelin and nerve fibers: A review\*

ALAN PETERS

*Department of Anatomy and Neurobiology, Boston University School of Medicine, 715, Albany Street, Boston, MA 02118, USA  
apeters@cajal-1.bu.edu*

Received 7 January 2003; revised 4 March 2003; accepted 5 March 2003

---

## Abstract

It was believed that the cause of the cognitive decline exhibited by human and non-human primates during normal aging was a loss of cortical neurons. It is now known that significant numbers of cortical neurons are not lost and other bases for the cognitive decline have been sought. One contributing factor may be changes in nerve fibers. With age some myelin sheaths exhibit degenerative changes, such as the formation of splits containing electron dense cytoplasm, and the formation on myelin balloons. It is suggested that such degenerative changes lead to cognitive decline because they cause changes in conduction velocity, resulting in a disruption of the normal timing in neuronal circuits. Yet as degeneration occurs, other changes, such as the formation of redundant myelin and increasing thickness suggest of sheaths, suggest some myelin formation is continuing during aging. Another indication of this is that oligodendrocytes increase in number with age.

In addition to the myelin changes, stereological studies have shown a loss of nerve fibers from the white matter of the cerebral hemispheres of humans, while other studies have shown a loss of nerve fibers from the optic nerves and anterior commissure in monkeys. It is likely that such nerve fiber loss also contributes to cognitive decline, because of the consequent decrease in connections between neurons.

Degeneration of myelin itself does not seem to result in microglial cells undertaking phagocytosis. These cells are probably only activated when large numbers of nerve fibers are lost, as can occur in the optic nerve.

## A reminiscence

When I was asked to contribute an article to this issue of *Journal of Neurocytology*, dedicated to Sandy Palay, I considered a number of possible topics and in the end decided to write about my recent studies of the effects of age on myelin sheaths. In a sense, this completes a circle, because I first met Sandy in 1960 in Delft when we were both at the European Regional Conference in Electron Microscopy: he talked about the neurosecretory cells in the preoptic nucleus of fishes and I gave a paper on the structure of myelin sheaths in the central nervous system. We met again the following year in London at the 1961 meeting of the Anatomical Society of Great Britain and Ireland, and I persuaded Sandy to come to Edinburgh in 1962 to give the Ramsey Henderson Trust Lectures. This was the beginning of a long friendship and a productive scientific association that culminated in the two of us collaborating with Harry Webster to write "The Fine Structure of the Nervous System", which was first published in 1970. This atlas with text ran into three editions, and is probably one of the most quoted books in neuroanatomy.

Since my association with Sandy had its beginnings in the structure of myelin, it seems appropriate for me to now return to that topic. Forty years ago, my interest was in the formation and structure of central myelin: now it is the other end of spectrum, how myelin sheaths react to aging and how their structure alters.

## Introduction

The majority of studies on the effects of aging on the nervous system have focused on the changes that occur as a consequence of Alzheimer's disease. This is understandable because the effects of this disease are devastating to both patients and their families, but because of this focus, the effects of normal aging on the nervous system received little attention and studies only began to appear frequently some 25 years ago. And yet as human longevity increases and brings about an increase in the number of citizens that are elderly, we need to understand what is happening to the brain during normal aging, and what underlies the cognitive declines

\*Grant sponsor: N.I.H. National Institute on Aging. Grant IPO AG 00001.

often associated with normal aging. Many older people show a decline in short term memory; increase in forgetfulness; increase in the time it takes to learn new information; and a slowing of the speed of response to challenging situations. Unfortunately, these cognitive changes can often affect the ability of older people to lead independent lives, and it is only by understanding what is happening in the aging nervous system that any possible alleviations can be proposed. Another reason for needing to know what is happening to the normally aging brain is that pathological changes, such as those occurring in Alzheimer's disease, can appear late in life, and are superimposed upon a background of the normal aging changes that have preceded them. Consequently it is important to know what types of changes are produced by normal aging and how they differ from the ones that are disease related.

### **The effects of normal aging on numbers of cortical neurons**

Studying the effects of normal aging on the human brain and correlating any alterations with declines in cognition presents problems. Delays in obtaining human tissue for examination after death result in deterioration of cells and their components, making it difficult to carry out useful morphological studies. In addition it is rare that the cognitive status of an individual has been accurately recorded before death. These factors undoubtedly played a role in the development of the popular concept that the cognitive decline associated with normal aging is brought about by a significant loss of cortical neurons.

In the first studies of the effects of age on the human cortex Brody (1955, 1970) concluded that as many as 50% of neurons are lost with age. Other investigators concurred with this conclusion (see Peters *et al.*, 1998), and it was not until the 1980s that Haug and Terry and their colleagues produced contrary evidence. Thus, Haug and his colleagues (Haug, 1984, 1985; Haug *et al.*, 1984) showed that many of the early reports of loss of cortical neurons with age could be attributed to the fact that upon fixation the brains of younger individuals shrink more than those of older ones, which have more myelin. Consequently, when sections of cortical tissue are examined, the young brains show higher neuronal packing densities than those of older individuals. After making corrections for this differential shrinkage, Haug and his colleagues concluded there is no significant loss of neurons from the human cerebral cortex with age. Terry *et al.* (1987) reached a similar conclusion and suggested that much of the neuronal loss recorded in earlier studies could be attributed to brains of some individuals with undiagnosed Alzheimer's disease being included among the older brains that were being eval-

uated and considered to be normal. In Alzheimer's disease there is a significant neuronal loss from cerebral cortex.

In recent studies of the effects of normal human aging more attention has been paid to the selection of the material being studied and to the way in which neurons are counted, and it is now generally agreed that although there might be a slight loss of cortical neurons during normal aging, it is nowhere as extensive as early reports would suggest (see Morrison & Hof, 1997; Peters *et al.*, 1998).

Because of the problems in obtaining adequately preserved human material some investigators have turned to non-human primates, such as the rhesus monkey, to study normal aging. The advantages of using non-human primates are that they have a life span of only 35 years (Tigges *et al.*, 1988), as opposed to the human life span of 75 to 90 years; they show cognitive deficits similar to those of humans; and they do not develop Alzheimer's disease. Furthermore, the cognitive status of the monkeys can be assessed by psychological tests adapted from those used on humans (*e.g.*, Bachevalier *et al.*, 1991; Albert & Moss, 1996; Herndon *et al.*, 1997) and brain tissue can be optimally preserved for morphological studies, so that useful correlations can be made between cognitive status and alterations in structure.

Interestingly, the first studies of the effects of age on the monkey brain also led to the conclusion that cortical neurons are lost with age (Brizzee, 1973; Brizzee *et al.*, 1975), but as with the human studies, more recent studies of the non-human primate cortex (summarized in Peters *et al.*, 1998) have concluded that there is no significant loss of cortical neurons with age from these non-human primates. This conclusion has led investigators to seek alternative explanations for the cognitive decline and to examine other components of the central nervous system. In our case, we have begun to focus on the effects of age on the myelinated nerve fibers in the cerebral hemispheres.

### **The formation of myelin**

The myelin sheaths in the central nervous system are produced by oligodendrocytes. During development, processes of oligodendrocytes enclose lengths of axons that are to be myelinated, and the outer faces of the trilaminar plasma membrane of the enclosing process come together to form a mesaxon. Subsequently the oligodendrocyte process elongates to form a spiral wrapping around the enclosed axon. In this wrapping the outer faces of the trilaminar plasma membrane in successive turns of the spiraling oligodendrocyte process come together to form what will be the intraperiod or intermediate line of the mature sheath. Eventually cytoplasm is eliminated from the spiraling oligodendrocyte process so that the cytoplasmic faces of the

trilaminar membrane also become apposed. This leads to the formation of the major dense line and to compact myelin sheaths (*e.g.*, Peters, 1960, 1964).

### The effects of aging on myelin sheaths

In our initial studies of the effects of aging on nerve fibers we chose to examine the nerve fibers within cerebral cortex (Peters *et al.*, 2000; Peters & Sethares, 2002), in which the myelin sheaths are usually much better preserved than those in white matter (Figs. 1 and 2). The reason is that the blood supply to white matter is relatively poor, so that obtaining good fixation of its myelin sheaths by perfusion fixation is always a problem, and in our initial studies it was important to differentiate structural changes that might occur as a result of poor fixation from those produced as a consequence of aging. In well-preserved cortical tissue the myelin around nerve fibers is generally compact, although some localized shearing defects may be encountered (Fig. 2). These shearing defects are fixation artifacts, because they occur in material from both young and old monkeys, and their frequency increases as the quality of preservation of tissue decreases. Where the shearing defects occur the myelin lamellae separate to produce a bulge (see Peters *et al.*, 2000).

Having established that shearing defects are due to poor fixation, and not to aging, we were able to extend our studies of the effects of aging to the myelin sheaths and nerve fibers in cerebral cortex (Peters *et al.*, 2000; Peters & Sethares, 2002); in corpus callosum (Peters & Sethares, 2002); in optic nerve (Sandell & Peters, 2001); in anterior commissure (Sandell & Peters, unpublished); and in the optic radiation. While shearing defects occur in each of these structures, and more commonly in white than in gray matter, there are other alterations in myelin that are age-related. Such alterations have been encountered in each of these structures, which suggests that they are ubiquitous.

### Sheaths with dense cytoplasm

The most common age-related defect is one in which myelin lamellae split at the major dense line to enclose dense cytoplasm (Figs. 1, 2, and 4). The amount of dense cytoplasm varies, and it may contain inclusions, lysosomes, and vacuoles. When the amount of dense cytoplasm is small it produces only a minor splitting, but in extreme cases the dense cytoplasm can be voluminous and occupy splits within several adjacent portions of the turns of the spiralling lamellae (Fig. 2). Since the dense cytoplasm is contained within splits of the major dense line, which is produced by apposition of the cytoplasmic faces of the oligodendroglial plasma membrane forming the myelin, it must be derived from the parent oligodendrocyte. It is presumed

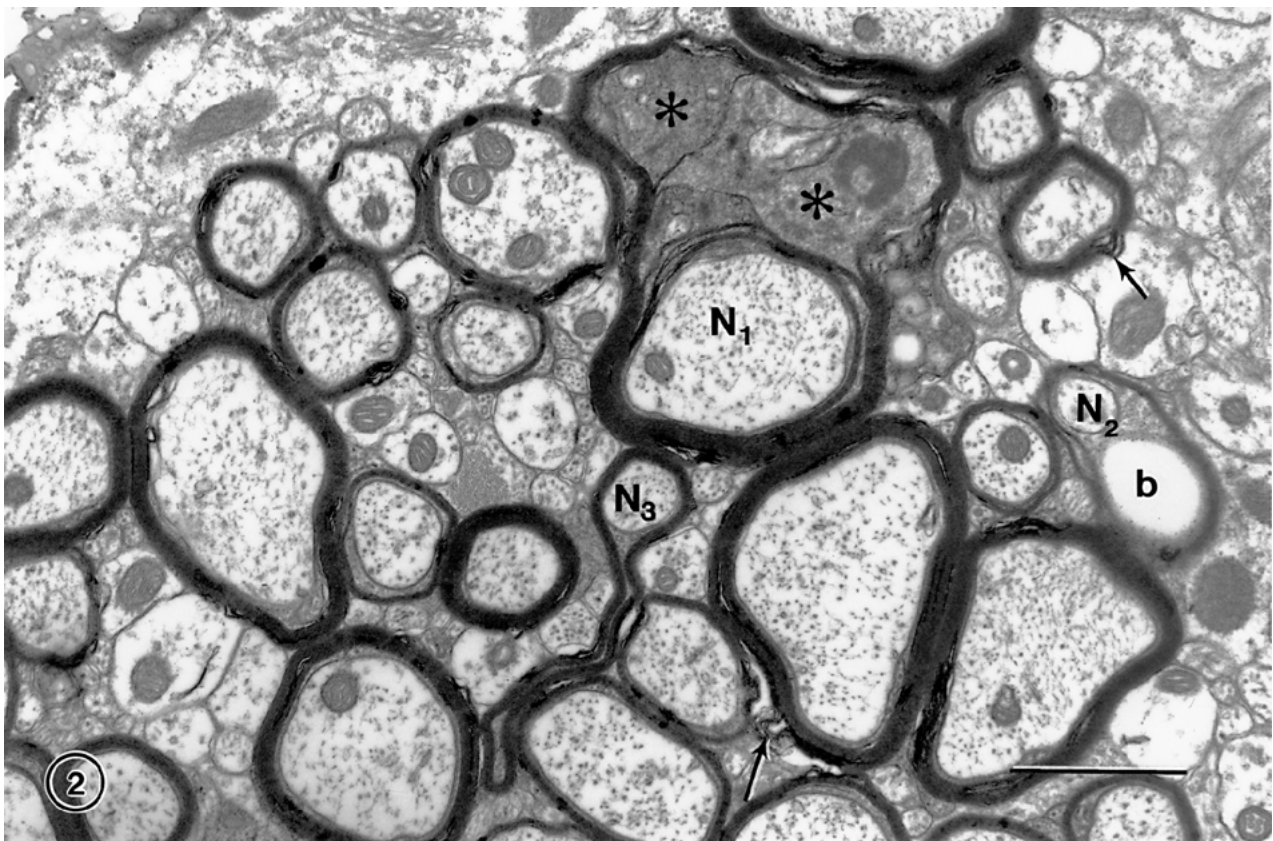
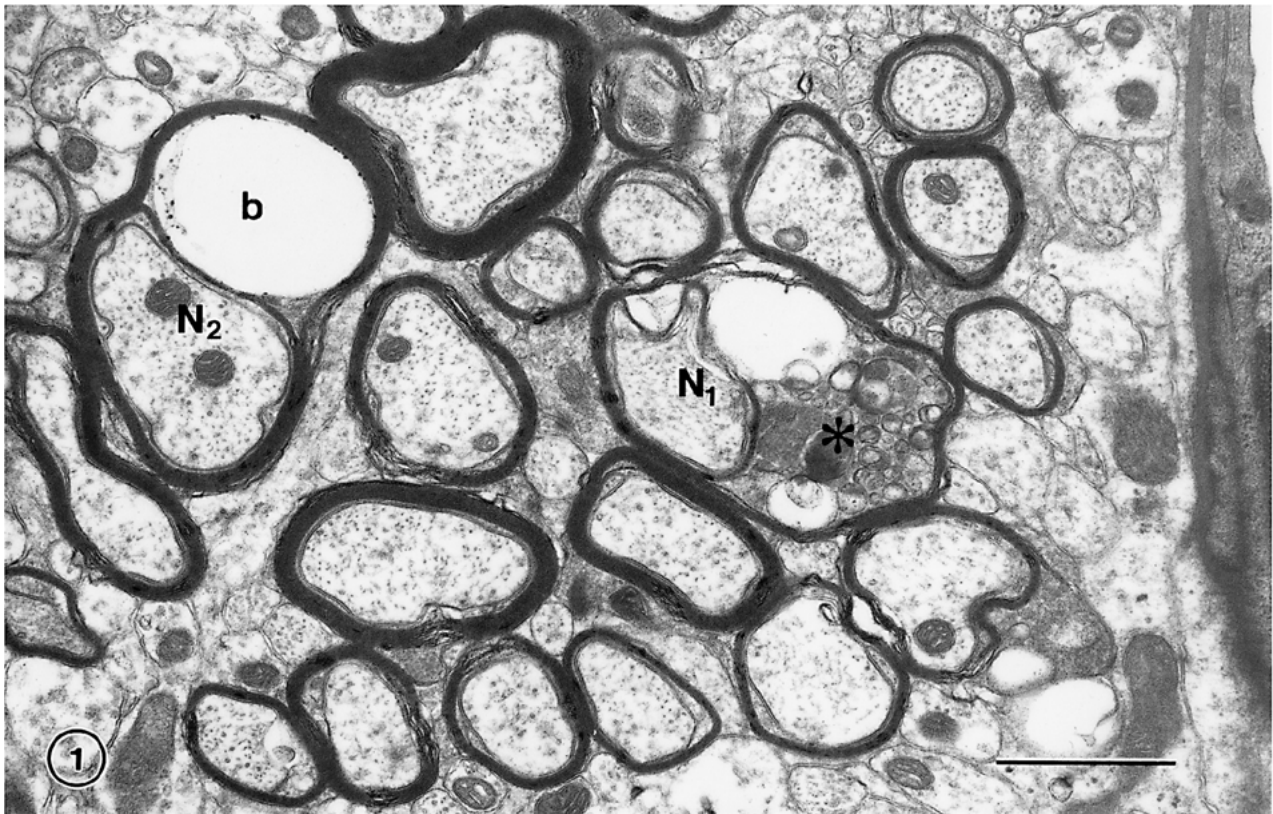
that the presence of the dense cytoplasm within a sheath is an indication that it is degenerating, since Cuprizone toxicity leads to the formation of dense cytoplasm in the inner tongue processes of degenerating sheaths (Ludwin, 1978, 1995), and similar dense cytoplasm occurs in the sheaths of mice with a myelin-associated glycoprotein (MAG) deficiency (*e.g.* Lassmann *et al.*, 1997).

### Myelin balloons

A second type of age-related change in myelin sheaths is the formation of "balloons" (Feldman & Peters, 1998). In light microscopic preparations these balloons appear as holes, but electron microscopy reveals that they are round, and often spherical, cavities that cause the myelin sheaths to bulge out (Figs. 1–3). Small balloons are only a micron or so in diameter, while at the other extreme are balloons that can achieve diameters of ten or more microns. Some of the small balloons are produced by cavitation of the cytoplasm on the inside of the myelin sheath (Fig. 2), but the larger ones are fluid filled spheres, the fluid being contained in a balloon produced by a splitting of the intraperiod line of the compact myelin on one side of the nerve fiber. In favorable transverse sections through affected nerve fibers the axon can be seen flattened against one side of the fluid filled balloon (Fig. 3). However, sometimes the axon is not visible in sections through large balloons, and it is presumed that such images are produced by sections that pass in a plane parallel to, and to one side of, the nerve fiber. Obviously the formation of large balloons must entail the insertion of a significant amount of new myelin membrane into an existing sheath by the parent oligodendrocyte.

Balloons have also been described in the cochlear nucleus of the aging gerbil (Faddis & McGinn, 1997), and it is presumed that the ballooning of myelin sheaths is a degenerative change, since similar balloons can be produced experimentally. For example, ballooning of myelin occurs in severe diabetes (Tamura & Parry, 1994) and in early phases of Wallerian degeneration in the dorsal funiculus of the spinal cord when myelin breaks down as a consequence of dorsal rhizotomy (Franson & Ronnevi, 1989). Similar balloons are formed in experimental toxicity produced by triethyl tin (*e.g.*, Hirano, 1969; Malamud & Hirano, 1973); by chronic copper poisoning (Hull & Blakemore, 1974); by Cuprizone poisoning (Ludwin, 1978); and by lysolecithin (Blakemore, 1978). In addition, balloons occur in genetically engineered mice that have either a deficit or an excess of proteolipid protein (Monuki & Lemke, 1995; Anderson *et al.*, 1998), and in mutant mice that lack galactolipids (Coetzee *et al.*, 1996, 1998).

The conditions leading to the inclusion of dense oligodendrocytic cytoplasm within myelin sheaths and to the formation of balloons suggest that they are both



degenerative, age-related alterations that affect the integrity of myelin sheaths. It should be pointed out however, that both of these changes are localized and do not extend along the entire length of an internode. This can be seen in longitudinal sections of affected nerve fibers (Fig. 4), and several of these loci of degeneration may occur along the same internode.

### Continued myelin production: Split sheaths and redundant myelin

Two other age-related changes in myelin sheaths are the increase in the frequency of appearance of sheaths with redundant myelin (Fig. 2) and the formation of circumferential splits in thick sheaths (Fig. 3). These alterations appear to be due to the continued formation of myelin with age. That myelin production continues with age is evident when the average thickness of myelin sheaths in layer 4 of monkey visual cortex is compared in young (4 to 9 years old) and old (over 24 year of age) monkeys (Peters *et al.*, 2001). The mean number of lamellae in the sheaths from the young monkeys is 5.6 and in old monkeys it is 7.0. Much of this increase in mean thickness is due to the increased frequency in old monkeys of sheaths with more than 10 lamellae. It is these thicker sheaths that show circumferential splitting, often giving the impression that they are composed of two separate sets of compact lamellae.

Sheaths of redundant myelin were first described by Rosenbluth (1966) and Sturrock (1976) found them to be more common in the white matter of old than young mice. In transverse sections of these nerve fibers the sheath of compact myelin is much too large for the enclosed axon, so that the axon is located at one end of a large loop of myelin (Fig. 2). It seems reasonable to suggest that the formation of sheaths with redundant myelin is due to a continued, perhaps uncontrolled, production of myelin with age.

### Altered myelin sheaths and conduction velocity

When the frequency of occurrence of these age-related changes in myelin are quantified in monkeys it is evident that there is a significant correlation between increasing frequency and increasing age. The frequency of occurrence of alterations in myelin sheaths in primary visual cortex (Peters *et al.*, 2000) and in area 46 of

prefrontal cortex (Peters & Sethares, 2002) also correlate significantly with the decline in cognitive behavior that occurs with increasing age in monkeys (*e.g.* Moss *et al.*, 1999). It is suggested that the reason for this correlation between myelin sheath alterations and decline in cognition is because damage to myelin sheaths results in a decrease in conduction velocity along nerve fibers. For example, Xi *et al.* (1999) found that compared with young cats the conduction velocity along nerve fibers in the pyramidal tracts of old cats is decreased by 43%, and Morales *et al.* (1987) have also shown that there is a decrease in conduction velocity of lumbar spinal neurons in old cats. Aston-Jones *et al.* (1985) have shown that compared to normal adults there is a 31% lengthening of conduction latencies from nucleus basalis to frontal cortex in old rats. Also in proteolipid protein (PLP) deficient mice, in which the myelin is loose or decompacted (Gutiérrez *et al.*, 1995) conduction velocity is reduced, as it is in nerve fibers that have lost one or more myelin internodes due to the effects of multiple sclerosis (*e.g.*, Waxman *et al.*, 1995; Felts *et al.*, 1997). Consequently, there is strong evidence that age and loss of myelin integrity reduces conduction velocity along nerve fibers, and it is suggested that the age-related alterations in the structure of myelin reduce conduction velocity. The result would be to cause a disruption in the timing of sequential events in neuronal circuits, and could lead to slowing of responses and difficulty in recalling information, as occurs in older individuals.

### The effects of age on oligodendrocytes

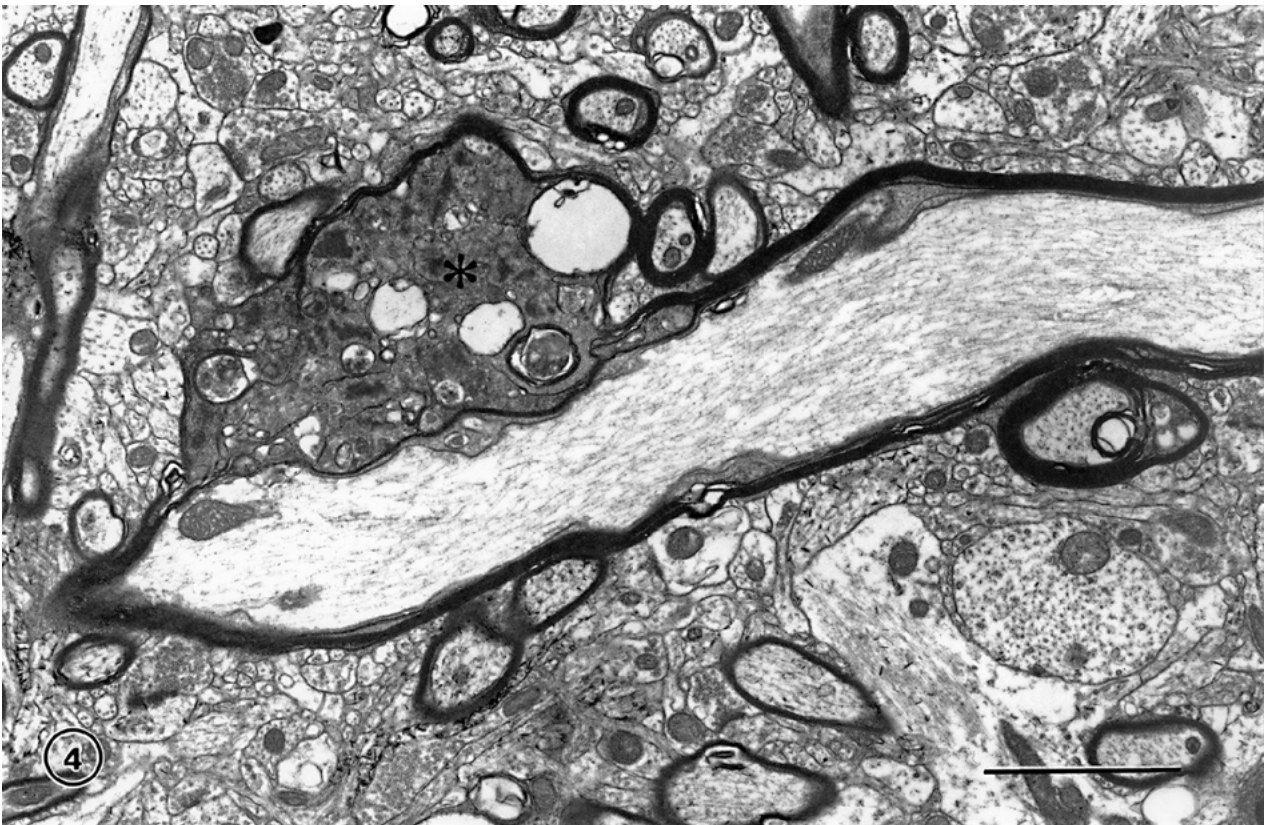
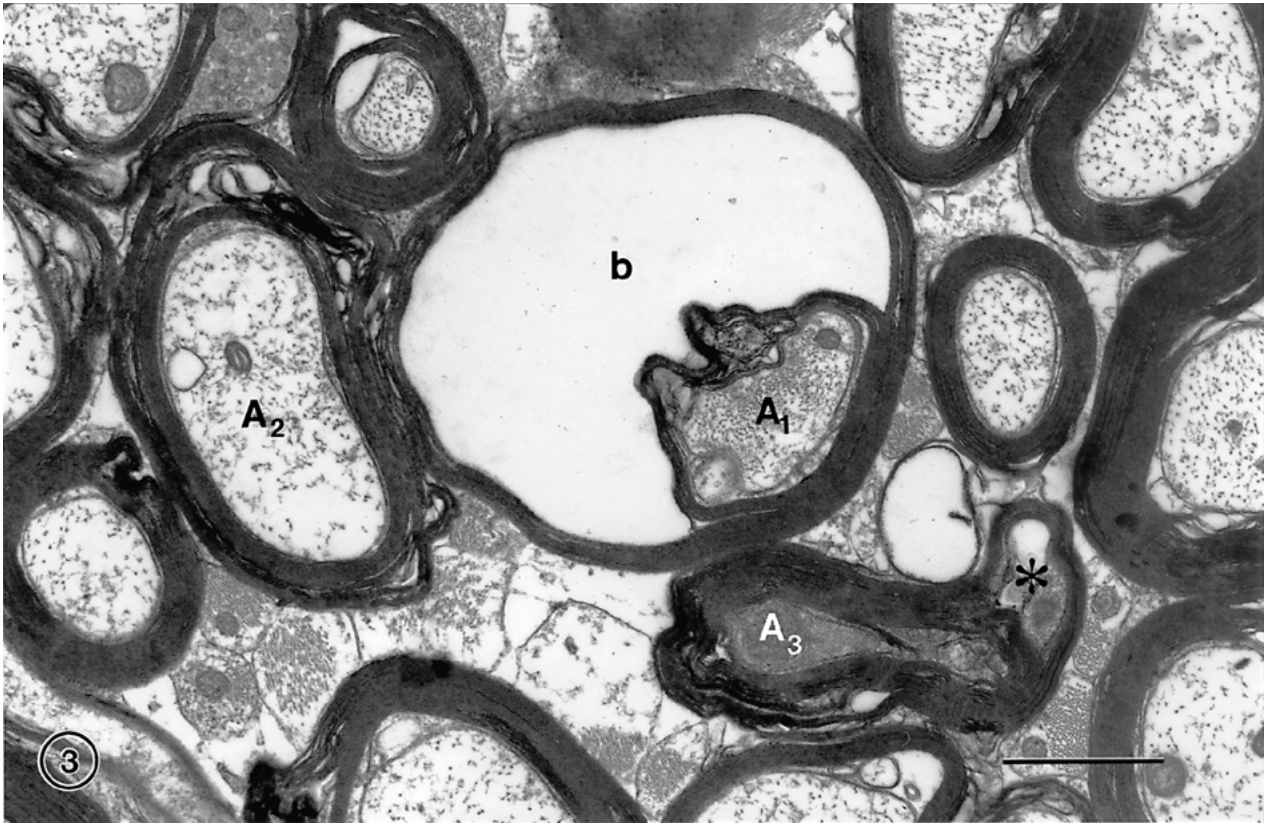
From the above it is apparent that the effects of age on myelin are complex, because even though some myelin sheaths are degenerating, there is a concomitant continued production of myelin. This raises the question of whether there are changes in the myelin-forming oligodendrocytes during normal aging.

When oligodendrocytes in the cerebral cortices of young and old monkeys are compared (Peters, 1996), it is seen that with age these cells accumulate increasing numbers of dense inclusions in their perikarya and that their processes develop swellings, which also contain dense inclusions (Figs. 5 and 6). The source of the material in these dense inclusions is not known, but since the inclusions are not bound by membrane, it is unlikely that they are derived from phagocytosis. More likely

---

**Fig. 1.** Tangential section through layer 4C of the visual cortex of a 32 years old rhesus monkey. One of the nerve fibers ( $N_1$ ) has a split myelin sheath, which contains dark cytoplasm (asterisk) with various inclusions. Another nerve fiber ( $N_2$ ) has a sheath that has split to accommodate a small fluid filled balloon (b.) Scale bar = 1  $\mu$ m.

**Fig. 2.** Tangential section through layer 4C of the visual cortex of a 29 year old rhesus monkey. One nerve fiber ( $N_1$ ) has a sheath with several splits that contain dark cytoplasm (asterisk), while another nerve fiber ( $N_2$ ) has a small balloon (b). Also contained in the field is a nerve fiber ( $N_3$ ) with redundant myelin. Note the shearing defects in some of the sheaths (arrows). Scale bar = 1  $\mu$ m.



the dense material is related to the activity of the oligodendrocytes, although in tissue sections labeled with antibodies to myelin basic protein no label was found to be present over the inclusions (Peters & Sethares, 2003).

One obvious question is whether the oligodendrocytes with dense inclusions are connected to sheaths that are degenerating and have dense material within them. This is not known because of the inherent difficulty in the mature brain of tracing connections between the myelin sheaths and their parent cells. One clue that the dense material might originate from degenerating sheaths comes from the study by LeVine and Torres (1992), who studied the twitcher mouse, which provides a model for globoid cell leukodystrophy. They found that the processes of some of the oligodendrocytes in these animals have large swellings adjacent to their myelin sheaths, while in others the swellings occur along the lengths of their processes. Their observations led LeVine and Torres (1992) to suggest that material in these swellings comes from turnover of material in the sheaths and that the material moves from the sheath, along the processes, to their cell bodies. If this is so, the dense inclusions in the oligodendritic processes and cell bodies are probably derived from the breakdown of some of the myelin sheaths. To assess this possibility it would be useful to determine the composition of the dense inclusions.

The fact that some myelin sheaths are degenerating with age would suggest that the parent oligodendrocytes are not able to maintain their sheaths and there may be a number of reasons for this, because oligodendrocytes are particularly susceptible to damage by a number of substances. For example they can be adversely affected by complement produced by macrophages; by cytokines; by nitric oxide; by changes in intracellular calcium and glutamate levels (*e.g.* Ludwin, 1997); and by oxidative stress (*e.g.*, Juurlink *et al.*, 1998.). However, apart from the dense inclusions that occur in their cytoplasm, no structural alterations have been seen in the oligodendrocytes in our preparations, and only one or two profiles that might be dying oligodendrocytes have been encountered.

On the other hand there is some evidence that in cerebral cortex the numbers of oligodendrocytes increases with age (Peters *et al.*, 1991), and this is supported by the fact that while oligodendrocytes usually occur singly in young monkeys, in the cortices of old monkeys it is

common to see oligodendrocytes in groups and rows (Fig. 6), which have probably been produced by cell division (Peters, 1996).

It might be suggested that additional oligodendrocytes are required to remyelinate axons with lengths that have been left bare as a result of degeneration of some of their internodes. But it is unlikely that additional cells are derived from mature oligodendrocytes attached to myelin sheaths (*e.g.* Ludwin & Bakker, 1988; Norton, 1996). More likely they are derived from oligodendroglial progenitor cells that are present in the mature central nervous system (*e.g.*, Levine *et al.*, 2001) and can be labeled with antibodies such as those to the NG2 proteoglycan and to the platelet derived growth factor receptor  $\alpha$  (PDGF $\alpha$  receptor). It is known that gliogenesis does not cease in the mature mammalian central nervous system, and while both astrocytes and oligodendrocytes appear to be produced from the progenitor cells initially, with increasing age oligodendrocytes are preferentially generated (Levison *et al.*, 1999; Parnavelas, 1999). This generation of new oligodendrocytes is of great interest because of the potential of these cells to remyelinated axons following demyelinating lesions, such as those that occur after injury or in multiple sclerosis (*e.g.*, Carroll & Jennings, 1994; Carroll *et al.*, 1998; Levison *et al.*, 1999; Jones *et al.*, 2002).

### Loss of nerve fibers

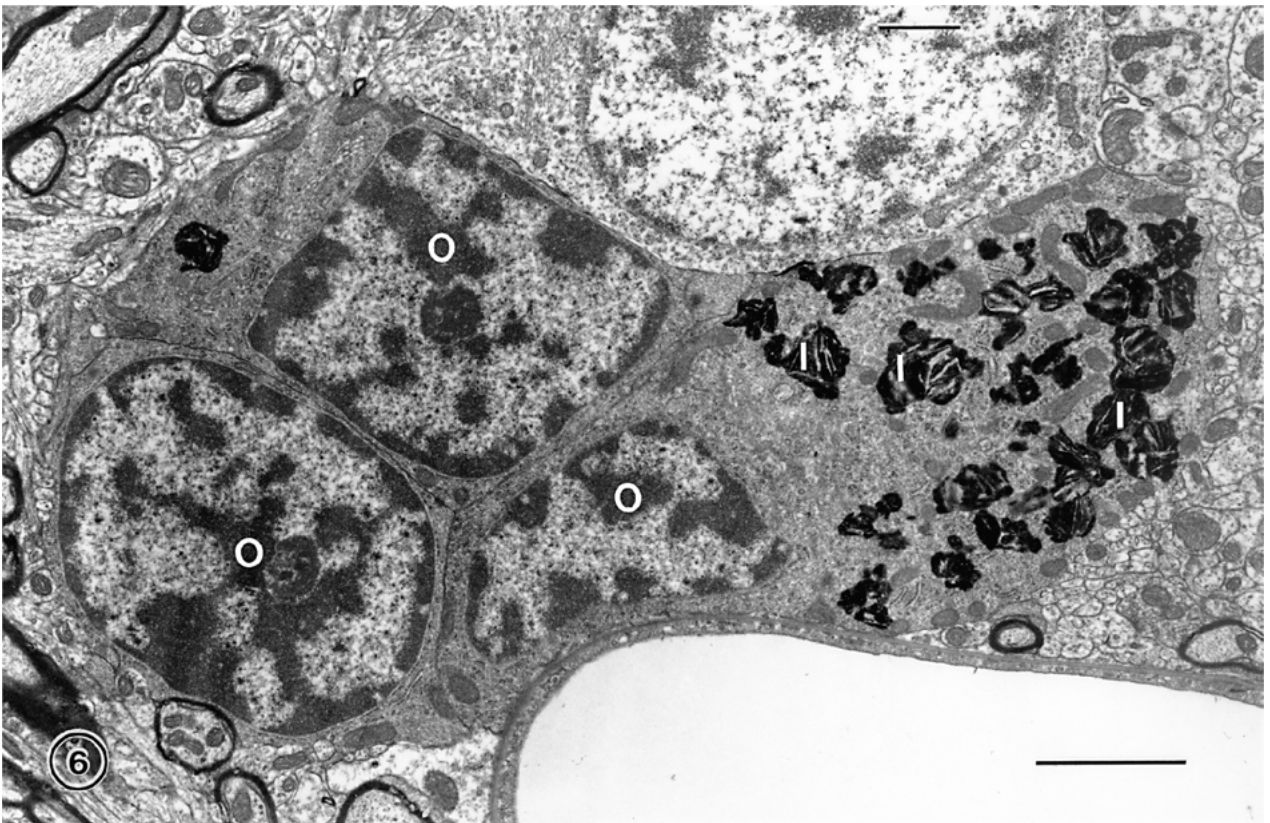
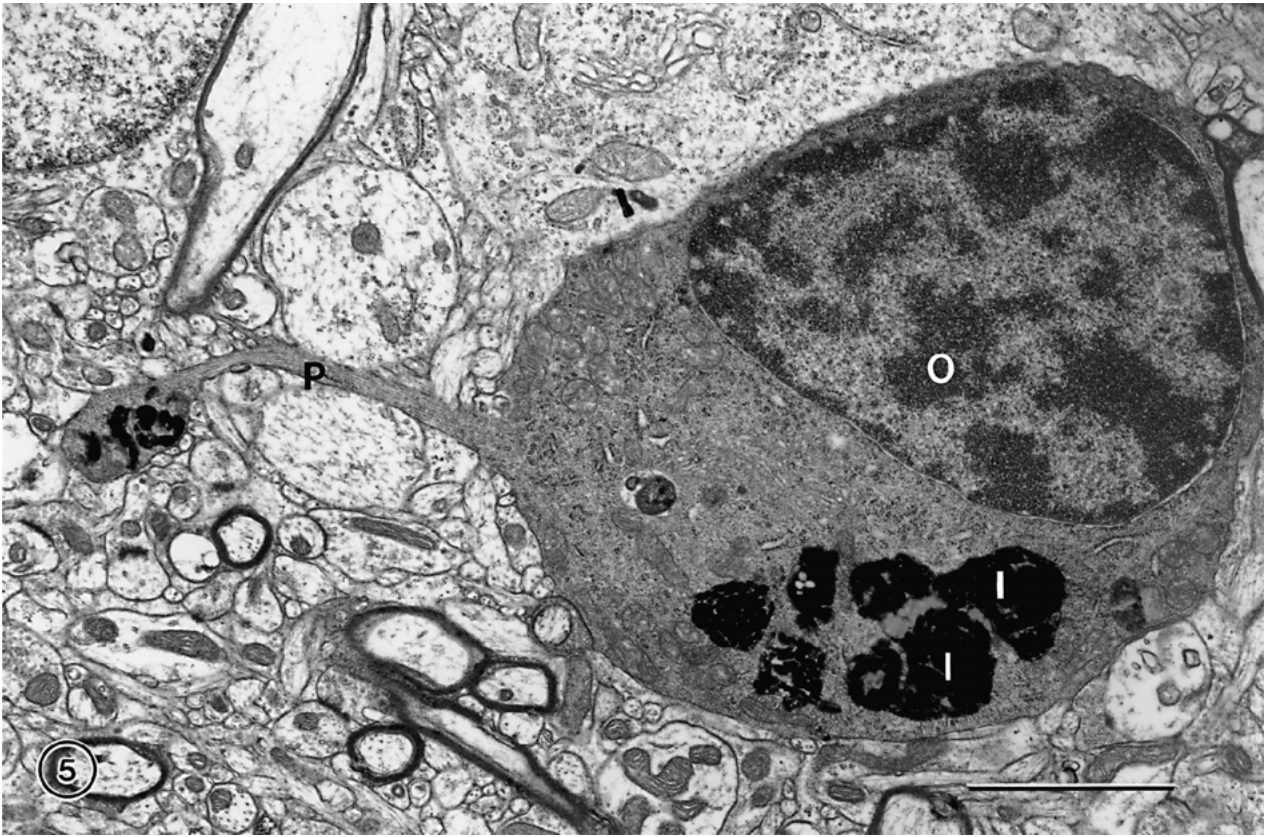In cerebral cortex Lintl and Braak (1983) observed that the intensity of staining of nerve fibers in the stripe of Gennari in the human cortex decreases with age and they suggested that this is due to a loss of nerve fibers. However, in the primary visual cortex of the monkey, even though there is evidence for a breakdown of myelin, there is no evidence of a significant loss of nerve fibers with age (Nielsen & Peters, 2000). Nevertheless, there is probably some small loss of nerve fibers from cerebral cortex with age because a few profiles of nerve fibers with dystrophic axons containing large numbers of mitochondria (Fig. 7), and others containing degenerating axons with dark cytoplasm (Fig. 8) can be found. In contrast, significant numbers of nerve fibers are probably lost from white matter with age.

Similar to the observation by Lintl and Braak (1983) and Kemper (1994) drew attention to the fact that in the cerebral hemispheres of the normal primates the staining of white matter in old brains is paler than in young

---

**Fig. 3.** Optic radiation from a 31 year old rhesus monkey. In the middle of the field is a nerve fiber with a large fluid filled balloon (b) that has pushed the axon (A<sub>1</sub>) to one side of the sheath. On the left is an axon (A<sub>2</sub>) with a thick sheath showing several circumferential splits. Another nerve fiber in this field has a split sheath (\*) and the axon (A<sub>3</sub>) has electron dense cytoplasm, which is an indication that the axon is degenerating. Scale bar = 1  $\mu$ m.

**Fig. 4.** A longitudinally sectioned nerve fiber in area 46 of prefrontal cortex from a 32 year old rhesus monkey. The sheath of the nerve fiber has split and bulges out because of the accumulation of dense cytoplasm within it (asterisk). Scale bar = 2  $\mu$ m.





brains, and stereological analyses (e.g. Pakkenberg & Gundersen, 1997; Tang *et al.*, 1997) indicate that there is a loss of white matter volume from the cerebral hemispheres of humans with age. Tang *et al.* (1997), for example, estimate that with age there is a 15 to 17% loss of white matter from the cerebral hemispheres, with a concomitant 27% reduction in the total length of myelinated nerve fibers. There is also MRI data on humans (Albert, 1993; Guttman *et al.*, 1998) and on monkeys (Lai *et al.*, 1995) that concur with this conclusion. However, there are other studies, such as the one by Andersen *et al.* (1999) on the brains of rhesus monkeys, suggesting that gray matter loss exceeds white matter loss. The reason for these different conclusions drawn from MRI studies may be the difficulty in knowing exactly where to place the boundary between white and gray matter in scans of the cerebral hemispheres.

In an attempt to resolve the issue of whether nerve fibers are lost with age we have begun to examine well-defined fiber tracts. In the first study we examined the optic nerves of rhesus monkeys (Sandell & Peters, 2001) and found that the number of nerve fibers is reduced from an average of  $1.6 \times 10^6$  in young optic nerves to as few as  $4 \times 10^5$  in one old monkey. But in every old monkey examined some degenerating nerve fibers were evident and the nerve fiber packing density was always less than in the young monkeys. Consequently, there is no doubt that nerve fibers are lost from optic nerves with age, probably due to the degeneration of ganglion cells. We have now begun to examine the anterior commissure, as another example of a well-defined nerve fiber bundle, and preliminary data (Sandell & Peters, unpublished data) indicate that on average there is a loss of about 50% of nerve fibers from this bundle with age.

Thus the available stereological data indicate that there is a loss of myelinated nerve fibers from white matter with age. Such a loss would result in a diminution of connectivity between components of the central nervous system and add to the conduction velocity problems brought about by alterations in the structure of some myelin sheaths.

Neurologists have also observed changes in white matter with age. For example, O'Sullivan *et al.* (2001) have used diffusion tensor MRI to look for age-related alterations in white matter. They find that diffusional anisotropy, which is a marker of white matter tract integrity, is reduced in old subjects and decreases linearly with age. The white matter disruption is maximal in

frontal regions and O'Sullivan *et al.* (2001) consider that the consequent cortical disconnection is the basis for the age-related cognitive decline in normal aging. Cerebral white matter lesions have also been associated with cognitive dysfunction and in a large sample of elderly subjects De Groot *et al.* (2000) concluded that periventricular white matter changes have a dominant role in bringing about cognitive decline, due, perhaps, to interruptions in long connecting tracts in white matter.

The origins of nerve fibers that are lost from, or damaged in, the white matter of the cerebral cortices, are not known, but it is to be presumed that they originate from some of the projecting pyramidal cells in the cortex. However, if there is no significant loss of cortical neurons, then the projecting myelinated axons must degenerate without loss of the parent cell body. It is possible that the cortical neurons do not degenerate because they are sustained by the very extensive local plexuses that all pyramidal cells generate in the cortex itself.

#### Activation of neuroglial cells

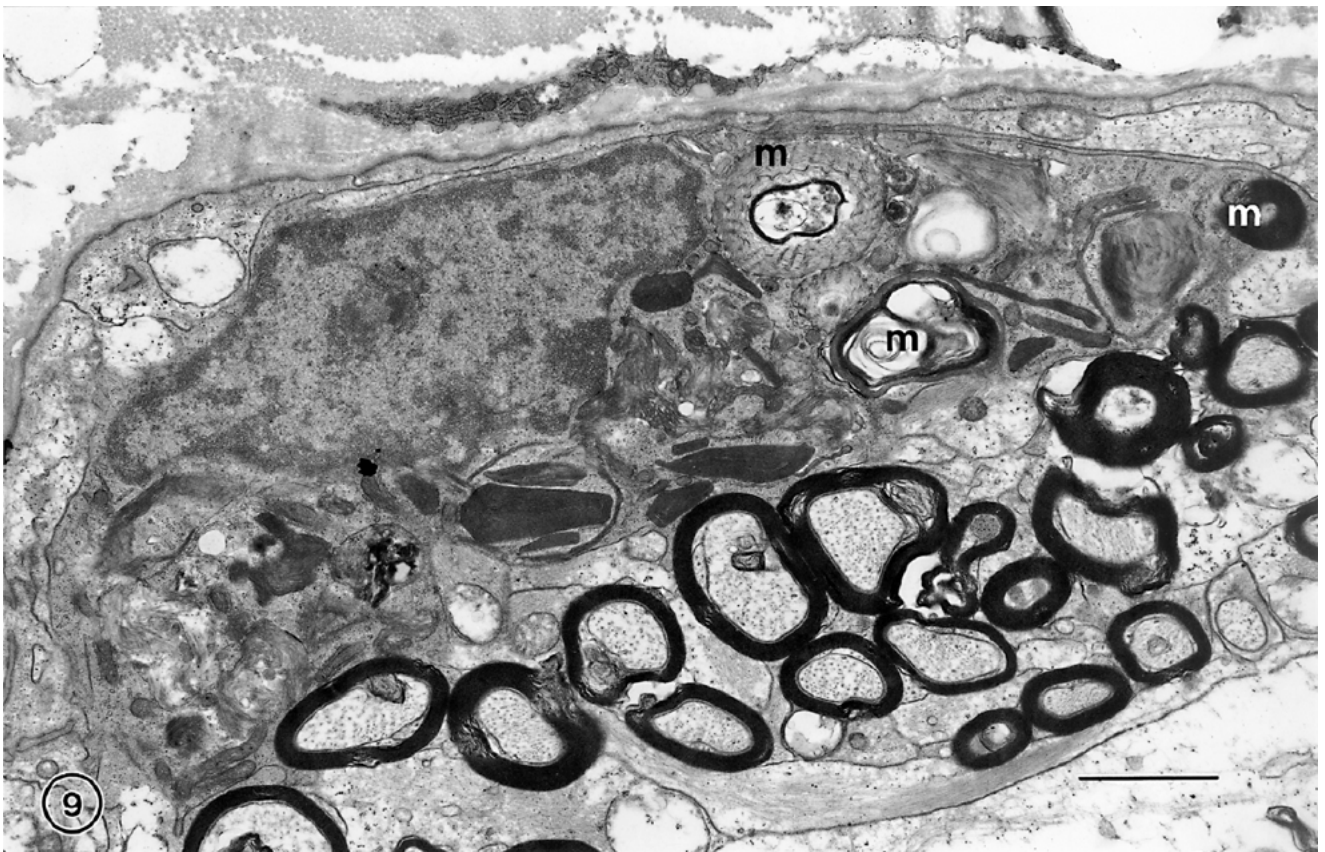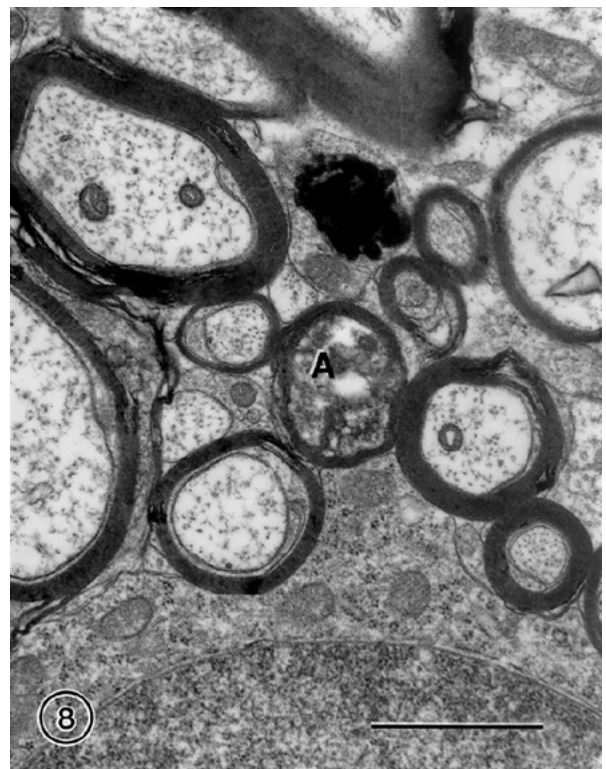
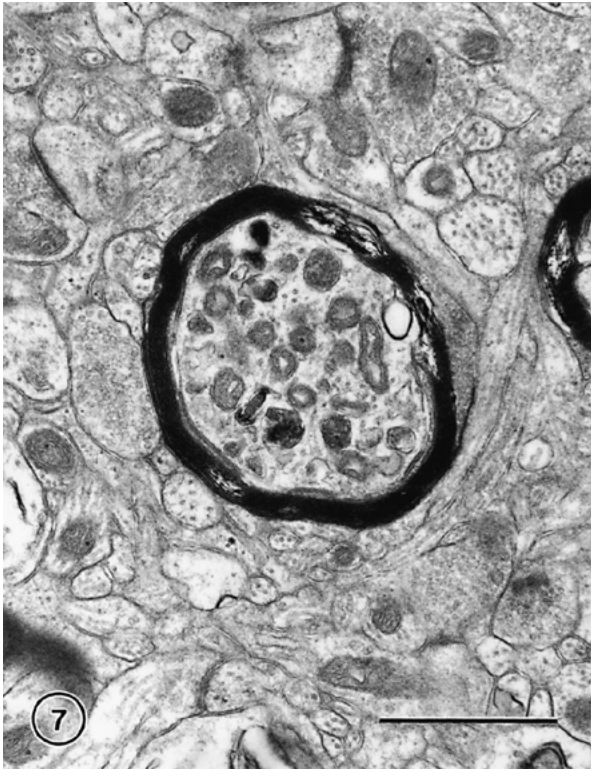
While there is evidence for degeneration of myelin sheaths in cerebral cortex with age, there is little evidence for extensive phagocytosis of myelin. A few astrocytes in old monkeys have been seen to contain myelin figures (e.g. Peters & Sethares, 2002) and in addition some of their amorphous inclusions bodies label with antibodies to myelin basic protein (MBP), which is one of the main constituents of myelin (Peters & Sethares, 2003). Microglial cells are usually regarded as the phagocytes of the central nervous system, and use of antibodies to HLA-DRm, a MHC class II antigen, indicates that microglial cells do become activated in the cerebral hemispheres of old monkeys (Sloane *et al.*, 1999). However, in cerebral cortex the microglia have no inclusions in their perikarya with the features of myelin, and their inclusions do not label with antibodies to myelin basic protein (MBP). Consequently, astrocytes appear to be the principal phagocytes of degenerating myelin in cerebral cortex, and our studies of fiber tracts suggest that it requires degeneration of entire nerve fibers to activate microglia to phagocytose degenerating myelin.

Thus in the optic nerve, from which significant numbers of nerve fibers are lost during normal aging (Sandell & Peters, 2002), both the oligodendrocytes and the microglial cells become more numerous with age.

---

**Fig. 5.** An oligodendrocyte in the visual cortex of a 35 year old rhesus monkey. The oligodendrocyte (O) has dark cytoplasm that contains dense inclusions (I). Similar inclusions are also present in the swelling along the process (P) extending from this cell. Scale bar = 2  $\mu$ m.

**Fig. 6.** A group of three oligodendrocytes (O) in the visual cortex of a 28 year old rhesus monkey. The cytoplasm of one of the oligodendrocytes has numerous dense inclusions (I). Scale bar = 2  $\mu$ m.



The astrocytes do not increase in number, but they develop abundant filaments and undergo hypertrophy to fill the space vacated by the degenerating nerve fibers. However, all three main types of neuroglial cells come to contain inclusions. The oligodendrocytes have the dark, sometimes lamellar, inclusions that are common in these cells throughout the aging brain, and the astrocytes also come to contain their characteristic inclusions. But in those old optic nerves with the most degenerating nerve fibers the microglia become engorged with debris, which can be recognized as degenerating myelin (Fig. 9). In many ways this parallels the activation of microglia that occurs when nerve fibers are damaged and undergo Wallerian degeneration (*e.g.*, Kreutzberg *et al.*, 1998).

### Conclusions

Although there is no evidence for a significant loss of cortical neurons during normal aging on the cerebral hemispheres, there is widespread damage to the myelin sheaths that ensheath their axons, as evidenced by structurally altered myelin sheaths observed in electron microscopic preparations. In the cerebral cortex of monkeys the frequency of the alterations in sheaths correlates significantly with a decline in cognitive status, and it is suggested that the basis of this correlation is that breakdown of myelin reduces the rate of conduction of the affected nerve fibers, which in turn alters the timing in neuronal circuits. In cerebral cortex there is no significant loss of nerve fibers with age, but in white matter there is evidence from a number of different sources that large numbers of nerve fibers may be lost. This loss presumably compromises the connectivity between various parts of the brain and must also contribute to cognitive decline.

In situations where there is breakdown of myelin and little loss of nerve fibers, as in cerebral cortex, microglial cells do not seem to respond to the breakdown of myelin sheaths, and the principal phagocytes appear to be astrocytes. But when there is more extensive loss of both axons and their myelin sheaths, as in the optic nerves, the microglial cells become activated to phagocytose the degenerating myelin.

Clearly, more studies need to be carried out before the affects of myelin sheath breakdown and of nerve fiber degeneration on cognitive decline can be properly as-

sessed, and it is likely that these changes are only two among many factors that bring about cognitive decline. For example, although there is no extensive loss of cortical neurons in normal aging, neurons do lose dendritic branches and spines, and there are alterations in the levels of some neurotransmitters and their receptors. But as pointed out earlier, studies on the effects of normal aging on the central nervous system are in their infancy, and we are nowhere near being able to appreciate all of the factors that change with age, and which ones are dominant in bringing about age-related cognitive decline.

### References

- ALBERT, M. (1993) Neuropsychological and neurophysiological changes in healthy adult humans across the age range. *Neurobiology of Aging* **14**, 623–625.
- ALBERT, M. & MOSS, M. B. (1996) Neuropsychology of aging: Findings in humans and monkeys. In *Handbook of the Biology of Aging*, 4th ed. (edited by SCHNEIDER, E. L., ROWE, J. W. & MORRIS, J. H.) pp. 217–233. San Diego: Academic Press.
- ANDERSEN, A. H., ZHANG, Z., ZHANG, M., GASH, D. M. & AVISON, M. J. (1999) Age-associated changes in rhesus CNS composition identified by MRI. *Brain Research* **829**, 90–98.
- ANDERSON, T. J., SCHNEIDER, A., BARRIE, L. A., KLUGMAN, M., McCULLOCH, M. C., KIRKMAN, D., KYRIADES, E., NAVE, K. A. & GRIFFITHS, I. R. (1998) Late onset neurodegeneration in mice with increased dosage of the proteolipid protein gene. *Journal of Comparative Neurology* **394**, 506–519.
- ASTON-JONES, G., ROGERS, J., SHAVER, R. D., DINAN, T. G. & MOSS, D. E. (1985) Age-impaired impulse flow from nucleus basalis to cortex. *Nature* **318**, 462–464.
- BACHEVALIER, J., LANDIS, L. S., WALKER, L. C., BRICKSO, M., MISHKIN, M., PRICE, D. L. & CORK, L. C. (1991) Aged monkeys exhibit behavioral deficits indicative of widespread cerebral dysfunction. *Neurobiology of Aging* **12**, 99–111.
- BLAKEMORE, W. F. (1978) Observations on remyelination in the rabbit spinal cord following demyelination induced by lysolecithin. *Neuropathology and Applied Neurobiology* **4**, 47–59.
- BRIZZEE, K. R. (1973) Quantitative studies of aging changes in cerebral cortex of rhesus monkey and albino rat with notes on effects of prolonged low-dose radiation in the rat. *Progress in Brain Research* **40**, 141–160.

**Fig. 7.** A nerve fiber in area 46 of prefrontal cortex of a 27 year old rhesus monkey. The dystrophic axon contains numerous mitochondria and a few lysosomes. Scale bar = 1  $\mu$ m.

**Fig. 8.** A degenerating nerve fiber in the optic radiation from a 31 year old rhesus monkey. The axon (A) of the nerve fiber is electron dense. Scale bar = 1  $\mu$ m.

**Fig. 9.** A microglial cell in the optic nerve of a 32 year old rhesus monkey. Many of the nerve fibers in this optic nerve are degenerating and phagocytosed myelin (m) is evident in the cytoplasm of the microglial cell. Scale bar = 2  $\mu$ m.

- BRIZZEE, K. R., KLARA, P. & JOHNSON, J. (1975) Changes in microanatomy, neurocytology and fine structure with aging. In *Neurobiology of Aging* (edited by ORDY, J. M. & BRIZZEE, K. R.) pp. 574–594. New York: Plenum Press.
- BRODY, H. D. (1955) Organization of the cerebral cortex. III. A study of aging in the human cerebral cortex. *Journal of Comparative Neurology* **102**, 511–516.
- BRODY, H. D. (1970) Structural changes in the aging nervous system. *Interdisciplinary Topics in Gerontology* **7**, 9–21.
- CARROLL, W. M. & JENNINGS, A. R. (1994) Early recruitment of oligodendrocyte precursors in CNS demyelination. *Brain* **117**, 563–578.
- CARROLL, W. M., JENNINGS, A. R. & IRONSIDE, L. J. (1998) Identification of the adult resting progenitor cell by autoradiographic tracking of oligodendrocyte precursors in experimental CNS demyelination. *Brain* **121**, 293–302.
- COETZEE, T., FUJITA, N., DUPREE, J., SHI, R., BLIGHT, A., SUSUKI, K. & POPKO, B. (1996) Myelination in the absence of galactocerebroside and sulfatide: Normal structure with abnormal function and regional instability. *Cell* **86**, 209–219.
- COETZEE, T., SUSUKI, K. & POPKO, B. (1998) New perspectives on the function of myelin galactolipids. *Trends in Neuroscience* **21**, 126–130.
- DE GROOT, J. C., DE LEEUW, F.-E., OUDKERK, M., VAN GIJN, J., HOFMAN, A., JOLLES, J. & BRETELER, M. (2000) Cerebral white matter lesions and cognitive function: The Rotterdam scan study. *Annals of Neurology* **47**, 145–151.
- FADDIS, B. T. & MCGINN, M. D. (1997) Spongiform degeneration of the gerbil cochlear nucleus: An ultrastructural and immunohistochemical evaluation. *Journal of Neurocytology* **26**, 625–635.
- FELDMAN, M. L. & PETERS, A. (1998) Ballooning of myelin sheaths in normally aged macaques. *Journal of Neurocytology* **27**, 605–614.
- FELTS, P. A., BAKER, T. A. & SMITH, K. J. (1997) Conduction along segmentally demyelinated mammalian central axons. *Journal of Neuroscience* **17**, 7267–7277.
- FRANSON, P. & RONNEVI, L.-O. (1989) Myelin breakdown in the posterior funiculus of the kitten after dorsal rhizotomy: A qualitative and quantitative light and electron microscopic study. *Anatomy and Embryology* **180**, 273–280.
- GUTIÉRREZ, R., BIOSON, D., HEINEMANN, U. & STOFFEL, W. (1995) Decompaction of CNS myelin leads to a reduction of the conduction velocity of action potentials in optic nerve. *Neuroscience Letters* **195**, 93–96.
- GUTTMAN, C. R. G., JOLESZ, F. A., KIKINIS, R., KILLIANY, R. J., MOSS, M. B., SANDOR, T. & ALBERT, M. S. (1998) White matter changes with normal aging. *Neurology* **50**, 972–978.
- HAUG, H. (1984) Macroscopic and microscopic morphometry of the human brain and cortex. A survey in the light of new results. *Brain Pathology* **1**, 123–149.
- HAUG, H. (1985) Are neurons of the human cerebral cortex really lost during aging? A morphometric examination. In *Senile dementia of the Alzheimer type* (edited by TABER, J. & GISPEN, W.) pp. 150–156. Berlin: Springer-Verlag.
- HAUG, H., KÜHL, S., MECKE, E., SASS, N.-L. & WASNER, K. (1984) The significance of morphometric procedures in the investigation of age changes in cytoarchitectonic structures of human brain. *Journal für Hirnforschung* **25**, 353–374.
- HERNDON, J., MOSS, M. B., KILLIANY, R. J. & ROSENE, D. L. (1997) Patterns of cognitive decline in early, advanced and oldest of the old aged rhesus monkeys. *Behavioral Research* **87**, 25–34.
- HIRANO, A. (1969) The fine structure of the brain in edema. In *The Structure and Function of Nervous Tissue*, Vol. 2 (edited by BOURNE, G. H.) pp. 69–135. New York: Academic Press.
- HULL, J. McC. & BLAKEMORE, W. F. (1974) Chronic copper poisoning and changes in the central nervous system of sheep. *Acta Neuropathologica* **29**, 9–24.
- JONES, L. J., YAMAGUCHI, Y., STALLCUP, W. B. & TUSZYNSKI, M. H. (2002) NG2 is a major chondroitin sulfate proteoglycan produced after spinal cord injury and is expressed by macrophages and oligodendrocyte progenitors. *Journal of Neuroscience* **22**, 2792–2803.
- JUURLINK, B. H. J., THORBURNE, S. K. & HERTZ, L. (1998) Peroxide-scavenging deficit underlies oligodendrocyte susceptibility to oxidative stress. *Glia* **22**, 371–378.
- KEMPER, T. L. (1994) Neuroanatomical and neuropathological changes during aging and dementia. In *Clinical Neurology of Aging* (edited by ALBERT, M. L. & KNOEFEL, J. E.) pp. 3–67. New York: Oxford University Press.
- KREUTZBERG, G. W., BLAKEMORE, W. F. & GRAEBER, M. B. (1998) Cellular pathology of the central nervous system. In *Greenfield's Neuropathology*, 6th ed. (edited by GRAHAM, D. I. & LANTOS, P. L.) pp. 85–156. London: Arnold.
- LAI, Z. C., ROSENE, D. L., KILLIANY, R. J., PUGLIESE, D., ALBERT, M. S. & MOSS, M. B. (1995) Age-related changes in the brain of the rhesus monkey: MRI changes in white matter but not gray matter. *Society for Neuroscience, Abstracts* **21**, 1564.
- LASSMANN, H., BARTSCH, U., MONTAG, D. & SCHACHNER, M. (1997) Dying-back oligodendroglial pathology: A late sequel of myelin-associated glycoprotein deficiency. *Glia* **19**, 104–110.
- LEVINE, J. M., REYNOLDS, R. & FAWCETT, J. W. (2001) The oligodendrocyte precursor cell in health and disease. *Trends in Neuroscience* **24**, 39–47.
- LEVINE, S. M. & TORRES, M. V. (1992) Morphological features of degenerating oligodendrocytes in twitcher mice. *Brain Research* **587**, 348–352.
- LEVISON, S. W., YOUNG, G. M. & GOLDMAN, J. E. (1999) Cycling cells in the adult rat neocortex preferentially generate oligodendroglia. *Journal of Neuroscience Research* **57**, 435–446.
- LINTL, P. & BRAAK, H. (1983) Loss of intracortical myelinated fibers: A distinctive alteration in the human striate cortex. *Acta Neuropathologica* **61**, 178–182.
- LUDWIN, S. K. (1978) Central nervous system demyelination and remyelination in the mouse. An ultrastructural study of cuprizone toxicity. *Laboratory Investigation* **39**, 597–612.

- LUDWIN, S. K. (1995) Pathology of the myelin sheath. In *The Axon: Structure, Function and Pathophysiology* (edited by WAXMAN, S. G., KOCSIS, J. D. & STYS, P. K.) pp. 412–437. New York: Oxford University Press.
- LUDWIN, S. K. (1997) The pathobiology of the oligodendrocyte. *Journal of Neuropathology and Experimental Neurology* **56**, 111–124.
- LUDWIN, S. K. & BAKKER, D. A. (1988) Can oligodendrocytes attached to myelin proliferate? *Journal of Neuroscience* **8**, 1239–1244.
- MALAMUD, N. & HIRANO, A. (1973) *Atlas of Neuropathology*. Berkeley: University of California Press.
- MONIKI, E. S. & LEMKE, G. (1995) Molecular biology of myelination. In *The Axon: Structure, Function and Pathophysiology* (edited by WAXMAN, S. G., KOCSIS, J. D. & STYS, P. K.) pp. 144–163. New York: Oxford University Press.
- MORALES, F. R., BOXER, P. A., FUNG, S. J. & CHASE, M. H. (1987) Basic electrophysiological properties of spinal cord motoneurons during old age in the cat. *Journal of Neurophysiology* **58**, 180–194.
- MORRISON, J. H. & HOF, P. R. (1997) Life and death of neurons in the aging brain. *Nature* **278**, 412–419.
- MOSS, M. B., KILLIANY, R. J. & HERNDON, J. G. (1999) Age-related cognitive decline in rhesus monkey. In *Neurodegenerative and Age-Related Changes in Structure and Function of the Cerebral Cortex*. *Cerebral Cortex*, Vol. 14 (edited by PETERS, A. & MORRISON, J. H.) pp. 21–48. New York: Kluwer Academic/Plenum Publishers.
- MOSS, M. B., KILLIANY, R. J., LAI, Z. C., ROSENE, D. L. & HERNDON, J. G. (1997) Recognition span in rhesus monkeys of advanced age. *Neurobiology of Aging* **18**, 13–19.
- NIELSEN, K. & PETERS, A. (2000) The effects of aging on the frequency of nerve fibers in rhesus monkey striate cortex. *Neurobiology of Aging* **21**, 621–628.
- NORTON, W. T. (1996) Do oligodendrocytes divide? *Neurochemical Research* **21**, 495–503.
- O'SULLIVAN, M., JONES, D. K., SUMMERS, P. E., MORRIS, R. G., WILLIAMS, S. C. R. & MARKUS, H. S. (2001) Evidence for cortical "disconnection" is a mechanism of age-related cognitive decline. *Neurology* **57**, 632–638.
- PAKKENBERG, B. & GUNDERSEN, H. J. G. (1997) Neocortical neuron number in humans: Effect of sex and age. *Journal of Comparative Neurology* **384**, 312–320.
- PARNAVELAS, J. G. (1999) Glial cells lineages in the rat cerebral cortex. *Experimental Neurology* **156**, 418–429.
- PETERS, A. (1960) The formation and structure of myelin sheaths in the central nervous system. *Journal of Biophysical and Biochemical Cytology* **8**, 431–446.
- PETERS, A. (1964) Observations on the connexions between myelin sheaths and glial cells in the optic nerves of young rats. *Journal of Anatomy* **98**, 125–134.
- PETERS, A. (1996) Age-related changes in oligodendrocytes in monkey cerebral cortex. *Journal of Comparative Neurology* **371**, 153–163.
- PETERS, A., JOSEPHSON, K. & VINCENT, S. L. (1991) Effects of aging on the neuroglial cells and pericytes within area 17 of the rhesus monkey cerebral cortex. *Anatomical Record* **229**, 384–398.
- PETERS, A., MORRISON, J. H., ROSENE, D. L. & HYMAN, B. T. (1998) Are neurons lost from the primate cerebral cortex during aging? *Cerebral Cortex* **8**, 295–300.
- PETERS, A., MOSS, M. B. & SETHARES, C. (2000) The effects of aging on myelinated nerve fibers in monkey primary visual cortex. *Journal of Comparative Neurology* **419**, 364–376.
- PETERS, A., NIGRO, N. J. & McNALLY, K. J. (1997) A further evaluation of the effects of age on striate cortex of the rhesus monkey. *Neurobiology of Aging* **18**, 29–36.
- PETERS, A. & SETHARES, C. (2002) Aging and the myelinated fibers in prefrontal cortex and corpus callosum of the monkey. *Journal of Comparative Neurology* **442**, 277–291.
- PETERS, A. & SETHARES, C. (2003) Is there remyelination during aging of the primate central nervous system? *Journal of Comparative Neurology*. Accepted for publication.
- PETERS, A., SETHARES, C. & KILLIANY, R. J. (2001) Effects of age on the thickness of myelin sheaths in monkey primary visual cortex. *Journal of Comparative Neurology* **435**, 241–248.
- ROSENBLUTH, J. (1966) Redundant myelin sheaths and other ultrastructural features of the toad cerebellum. *Journal of Cell Biology* **28**, 73–93.
- SANDELL, J. H. & PETERS, A. (2001) Effects of age on nerve fibers in the rhesus monkey optic nerve. *Journal of Comparative Neurology* **429**, 541–553.
- SANDELL, J. H. & PETERS, A. (2002) Effects of age on the glial cells in the rhesus monkey optic nerve. *Journal of Comparative Neurology* **445**, 13–28.
- SLOANE, J. A., HOLLANDER, W., MOSS, M. B., ROSENE, D. L. & ABRAHAM, C. R. (1999) Increased microglial activation and protein nitration in white matter of the aging monkey. *Neurobiology of Aging* **20**, 395–405.
- STURROCK, R. R. (1976) Changes in neuroglia and myelination in the white matter of aging mice. *Journal of Gerontology* **31**, 513–522.
- TAMURA, E. & PARRY, G. J. (1994) Severe radicular pathology in rats with longstanding diabetes. *Journal of Neurological Science* **127**, 29–35.
- TANG, Y., NYENGAARD, J. R., PAKKENBERG, B. & GUNDERSEN, H. J. G. (1997) Age-induced white matter changes in the human brain: A stereological investigation. *Neurobiology of Aging* **18**, 609–615.
- TERRY, R. D., DETERESA, R. & HANSEN, L. A. (1987) Neocortical cell counts in normal human adult aging. *Annals of Neurology* **21**, 530–539.
- TIGGES, J., GORDON, T. P., McCLURE, H. M., HALL, E. C. & PETERS, A. (1988) Survival rate and life span of rhesus monkeys at the Yerkes Regional Primate Research Center. *American Journal of Primatology* **15**, 263–272.
- WAXMAN, S. G., KOCSIS, J. D. & BLACK, J. A. (1995) Pathophysiology of demyelinated axons. In *The Axon: Structure, Function and Pathophysiology* (edited by WAXMAN, S. G., KOCSIS, J. D. & STYS, P. K.) pp. 438–461. New York: Oxford University Press.
- XI, M.-C., LIU, R.-H., ENGELHARDT, K. K., MORALES, F. R. & CHASE, M. H. (1999) Changes in the axonal conduction velocity of pyramidal tract neurons in the aged cat. *Neuroscience* **92**, 219–225.